A Comparison of Risk Between the Lateral Decubitus and the Beach-Chair Position When Establishing an Anteroinferior Shoulder Portal: A Cadaveric Study

Pablo Eduardo Gelber, M.D., Francisco Reina, M.D., Ph.D., Enrique Caceres, M.D., Ph.D., and Juan Carlos Monllau, M.D., Ph.D.

Purpose: The purpose of this study was to assess, using a technique that minimally distorts the normal anatomy, the risk of injury when establishing a 5 o'clock shoulder portal in the lateral decubitus versus beach-chair position. **Methods:** The anteroinferior portal was simulated with Kirschner wires (K-w) drilled orthogonally at the 5 o'clock position in 13 fresh frozen human cadaveric shoulders. The neighboring neurovascular structures were identified through an anteroinferior window made in the inferior glenohumeral ligament. Their relations to the K-w and surrounding structures were recorded in both positions. **Results:** The median distance from the musculocutaneous nerve to the K-w was shorter in the lateral decubitus position than in the beach chair position (13.16 mm *v* 20.49 mm, $P = .011$). The cephalic vein was closer to the portal in the beach-chair position than in the lateral decubitus position (median 8.48 mm *v* 9.93 mm, $P = .039$). The axillary nerve was closer to the K-w in the lateral decubitus position than in the beach-chair position (median 21.15 mm *v* 25.54 mm, $P = .03$). No differences in the distances from the K-w to the subscapular and anterior circumflex arteries were found when comparing both positions. The mean percentage of subscapular muscle height from its superior border to the K-w was 53.03%. **Conclusions:** This study showed the risk of injury establishing a transubscapular portal in either position. The musculocutaneous nerve and the cephalic vein are the most prone to injury. In general, the beach-chair position proved to be safer. **Clinical Relevance:** Inserting anchor devices orthogonally would permit stronger fixation but presents the risk of damaging neurovascular structures. This study focused on showing the neurovascular risk of performing full orthogonal insertion. Considering the good results reported with the usual superior-anterior portals, we do not recommend performing a transubscapular portal in routine shoulder arthroscopy. **Key Words:** 5 o'clock—Axillary nerve—Labrum—Inferior glenohumeral ligament—Bankart—Shoulder instability.

Capsulolabral reattachment was first advocated by Bankart[1] in the context of recurrent anterior shoulder instability. He performed it with a curved needle in an open procedure. Since then, many devices have been developed to reproduce his technique arthroscopically. Because of the neurovascular structures in the anteroinferior aspect of the shoulder joint, the arthroscopic placement of anchors in this region is most commonly performed from anterior or anterosuperior portals.[2] The orthogonal insertion of screw-in devices at the glenoid rim has recently shown the strongest fixation in cadaveric biomechanical studies.[3,4] These studies showed that minimal deviation from orthogonal insertion strongly affected the strength

From the Department of Orthopaedic Surgery, Hospital Universitari del Mar, Universitat Autònoma de Barcelona (P.E.G., E.C., J.C.M.), Barcelona, Spain; and Department of Morphological Sciences, Anatomy and Embryology Unit, Universitat Autònoma de Barcelona (P.E.G., F.R.), Barcelona, Spain.

The authors report no conflict of interest.

Address correspondence and reprint requests to Pablo Eduardo Gelber, M.D., Department of Orthopaedic Surgery, Hospital Universitari del Mar, Passeig Marítim 25-29, 08003 Barcelona, Spain. E-mail: pgelber@imas.imim.es

0749-8063/07/2305-6168$32.00/0
doi:10.1016/j.arthro.2006.12.034

of fixation in the anteroinferior glenoid quadrant. This makes the anchors to insert deviate superiorly. To drill them more perpendicularly to the glenoid rim, Davidson and Tibone[5] in 1995 and Resch et al.[6] in 1996 described a transubscapular portal. They advocated its use while minimizing the risk of neurovascular damage. They showed it in cadaveric and clinical models performed in the lateral decubitus position (LDP) and in a modified beach-chair position (BCHP) under traction. Davidson and Tibone performed this portal with an in-out technique, whereas Resch et al. described an out-in technique. Resch et al. performed the skin incision about 2 cm below the coracoid process. In contrast, Pearsall et al.[7] do not recommend the use of the 5 o'clock portal because of the high risk to the cephalic vein or humeral head chondral injury. They performed the study in the standard BCHP but generalized their recommendation to include the LDP.

These studies were performed by using methods that required extensive extra-articular dissections, which could distort the natural relations of anatomic structures. Moreover, a strictly orthogonal approach to the anteroinferior labrum is not achieved with the technique described by Davidson and Tibone[5] and Resch et al.[6] as shown in the study by Lo et al.[8]

The purpose of this study was to compare, with a method that minimally altered the normal anatomic relationships, the risk of damaging neurovascular structures when looking for a fully orthogonal anchoring in the glenoid rim in the LDP versus BCHP.

METHODS

Thirteen whole upper-extremity fresh-tissue shoulders (8 left and 5 right) from adult human volunteer donors were studied. Their ages ranged from 56 to 77 years. None of the shoulders showed macroscopic sign of previous surgery, and none had subscapularis tendon tears. Shoulders with moderate or severe glenohumeral arthritis were excluded from the study because it could alter the shape of the glena.

They were mounted on a shoulder holder (Extremity Holder, Sawbones, Sweden). When reproducing the LDP, the scapula was fixed so that the glena faced upright and parallel to the floor plane. The arms were abducted at 30° and flexed at 15°. Axial traction was performed with 3 kg hanging from the wrist via a pulley. The BCHP was performed with the tip of the scapula pointing forward 50° considering the coronal plane as the zero position, whereas the arm was at 20° of abduction and a neutral rotation. No traction was placed on the humerus in these cases. The glenohumeral position was calculated with the help of a manual goniometer. After each of the structures was measured in the LDP, the specimens were switched back and forth to the BCHP. A specially made external fixator kept the glenohumeral joint fixed in each case so that posterior manipulation could not alter this position.

A posterior approach was used to expose the joint. The skin was incised following the scapular spine and the posterolateral border of the acromion. It then curved inferiorly up to the union of the mid- and inferior third of the deltoid muscle. With an inferior incision, we finally configured a U-shaped approach. The deltoid muscle was released superiorly and laterally in line with the skin incisions. A 1.5 × 2.5-cm piece of the posterolateral aspect of the acromion was removed to better expose the rotator cuff. The infraspinatus and teres minor were then released from their humeral insertion and retracted medially. After upper-half capsulectomy and biceps tendon release from its origin, a humeral head osteotomy was performed. This allowed wide exposure and easier dissection of the anteroinferior aspect of the shoulder joint from an intra-articular perspective (Fig 1).

Subsequently, with the glena posteriorly exposed, 2.0 mm Kirschner wires (K-w) were drilled strictly orthogonally in a posterior to anterior direction at the 5 o'clock position. The K-w angled 30° laterally from posterior to anterior with respect to the glenoid artic-

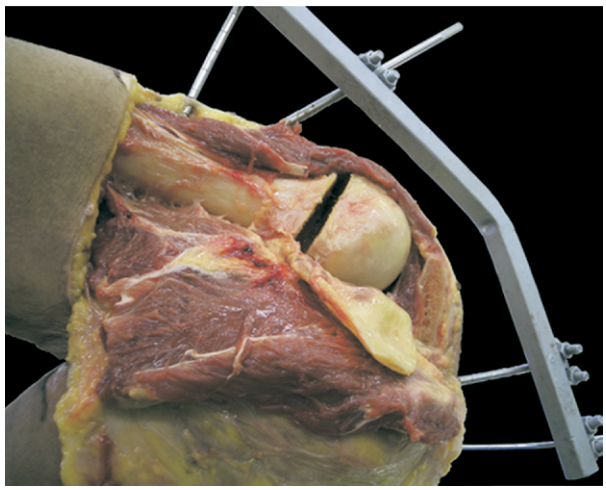

FIGURE 1. Posterior view of the left shoulder showing the humeral head osteotomy. The external fixator helps to maintain the simulated LDP.

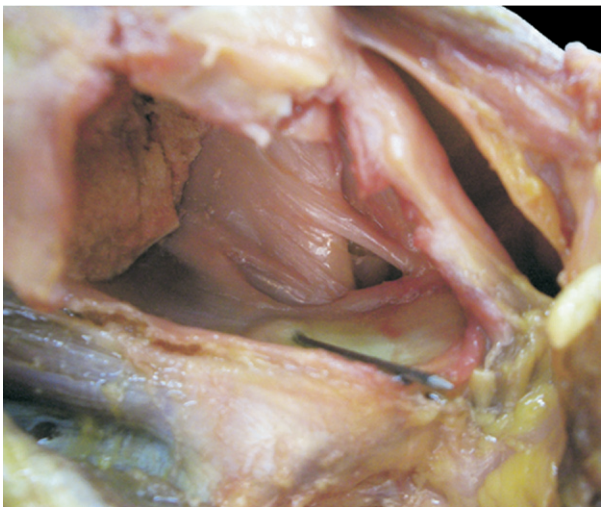

FIGURE 2. Intra-articular view of the glenohumeral joint after humeral head excision. The Kirschner wire exits the glenoid rim orthogonally at the 5 o'clock portal.

ular surface (Fig 2). This angle was calculated with the help of a small manual goniometer that was set over the anterior and posterior borders of the glena. A 2 × 2 inferior glenohumeral ligament window was made and excised by using microsurgical instruments under 3.5 magnification (OPMI-1; Zeiss, Jena, Germany).

The identification of the axillary nerve and anterior and posterior humeral circumflex arteries and their relationships with the K-w were recorded. After measurements both in the LDP and BCHP, a wide deltopectoral approach and a coracoid osteotomy were performed. Neurovascular structures that were beyond the reach from the intra-articular position were then recorded. The shortest distances from the K-w to the musculocutaneous nerve and cephalic vein were measured. Because the coracoid tip is a classic landmark used to calculate the safety area with respect to the musculocutaneous nerve, its relationship was also documented. The distance between the K-w and the deltopectoral groove, the deltoid branch of the thoracoacromial artery, and the subscapular artery were also recorded. In addition, the percentage of total subscapular height from its superior border to the K-w was calculated. All distances were determined with the help of an electronic digital caliper (Pro-Max, Fowler, Boston, MA; range 0 to 150 mm, resolution 0.02 mm). To minimally alter the anatomy when comparing the LDP and BCHP, each measurement was performed in both positions before evaluating other structures, and they were performed independently by 2 of the authors twice. The averages of the 2 measurements were then recorded.

Statistical Analysis

The statistical analysis was performed with the help of the SPSS 13.0 machine (SPSS, Chicago, IL). To estimate the agreement between observers, the intraclass correlation coefficient was calculated. For each variable, mean and standard deviation as well as median and quartiles were calculated. Because of the small sample number and the difficulty of determining whether the variables were or were not adjusted to a normal distribution, the Wilcoxon signed rank test was used to compare the measurements in both positions. Statistical significance was set at the 0.05 level.

RESULTS

Musculocutaneous Nerve

In 2 of the specimens, the musculocutaneous nerve was pierced by the K-w. In 1 case, the portal was established with the shoulder in the LDP (Fig 3), whereas in the other it was established in the BCHP. When the specimens were set at the LDP, the median distance from the musculocutaneous nerve to the K-w was shorter in comparison to the BCHP (13.16 *v* 20.49, $P = .011$) (Fig 4A). The distance from the coracoid tip to the musculocutaneous nerve averaged 47.76 mm. In 1 specimen, the nerve was only 22.6 mm distally from the coracoid tip.

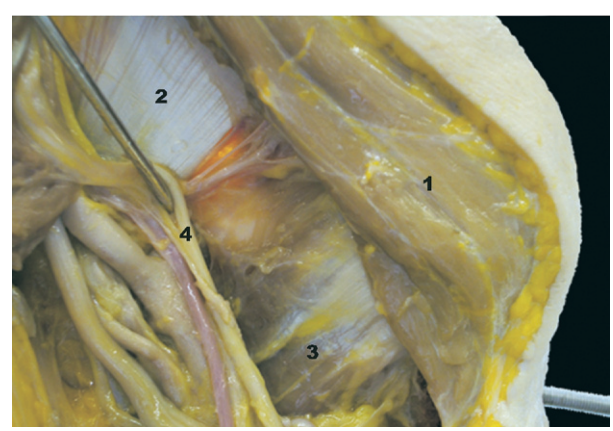

FIGURE 3. The musculocutaneous nerve pierced by the K-w is shown in this anterior view of a right shoulder in the LDP. In this specimen, the portal was established 2 mm below the inferior border of the subscapularis tendon and 48.96 mm distally from the coracoid tip. 1, deltoid muscle; 2, latissimus dorsi tendon; 3, subscapular muscle; 4, musculocutaneous nerve.

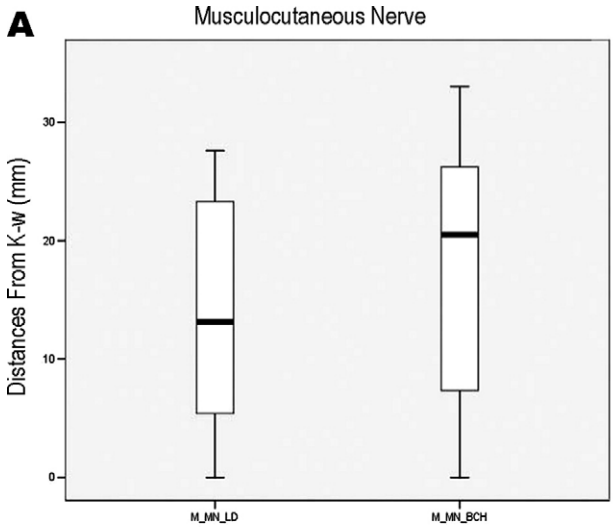

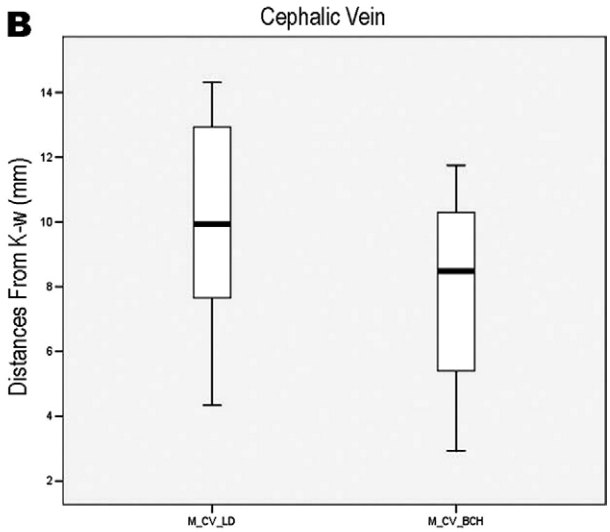

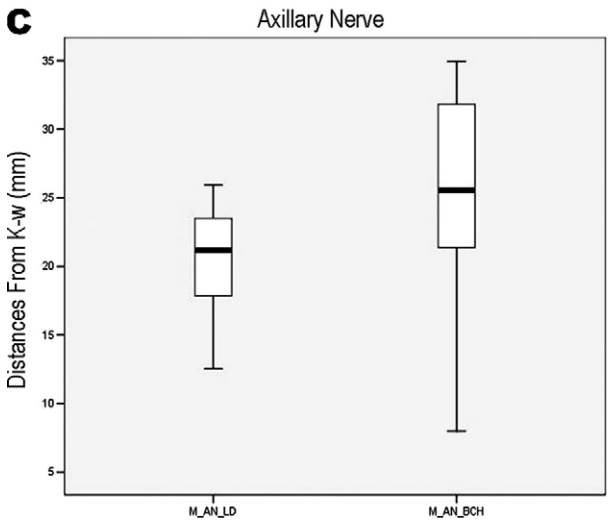

Figure 4. Median distances in millimeters from the orthogonal 5 o'clock portal comparing the LDP versus the BCHP with the (A) musculocutaneous nerve, (B) cephalic vein, and (C) axillary nerve. Abbreviations: M_MN_LD, median musculocutaneous nerve LDP; M_MN_BCH, median musculocutaneous nerve BCHP; M_CV_LD, median cephalic vein LDP; M_CV_BCH, median cephalic vein BCHP; M_AN_LD, median axillary nerve LDP; M_AN_BCH, median axillary nerve BCHP.

Deltopectoral Groove and Cephalic Vein

The position of the K-w with respect to the deltopectoral groove varied from 1 specimen to the other. In 7 shoulders, the K-w pierced the skin medially to the deltopectoral groove. In the other 6, it did so laterally (Fig 5). As shown in Figure 4B, the cephalic vein was closer to the portal in the BCHP than in the LDP (median 8.48 *v* 9.93, $P = .039$). Furthermore, the minimal distance observed was only 2.93 mm in the BCHP. Nevertheless, the proximity was also considerable in the LDP in the same specimen (4.33 mm).

Axillary Nerve and Other Structures

The distance of the K-w to the axillary nerve measured in the LDP had a median of 21.15 mm, whereas

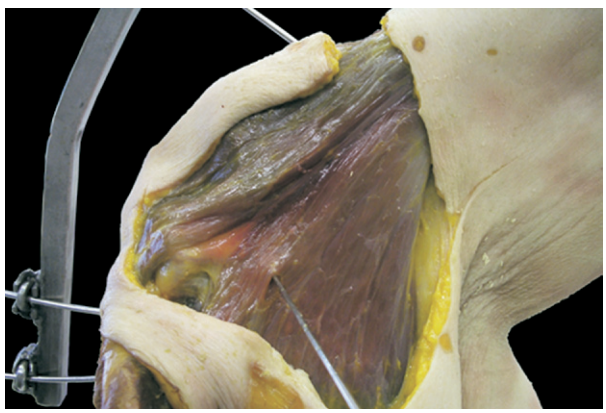

Figure 5. Anterior view of the left shoulder showing 1 case in which the portal was established medially to the deltopectoral groove. This might be partially explained for by those shoulders having a higher glenoid anteversion.

Figure 6. Posterior view of the right shoulder in the LDP. The terminal branches of the axillary nerve are seen passing to the posteroinferior aspect of the glenohumeral joint. The inferior glenohumeral ligament is observed between the nerve and the K-w. 1, inferior glenohumeral ligament; 2, axillary nerve.

the median was 25.54 (P = .03) in the BCHP (Fig 4C). In 1 specimen, the axillary nerve was only 4.34 mm away from the K-w in LDP, moving away to 7.98 mm in the BCHP (Fig 6).

In the present study, we found no differences in the distance from the K-w to the subscapular artery (35.04 *v* 38.29 mm, P = .308) and to the anterior circumflex artery (19.6 *v* 21.16 mm, P = .116) when comparing the LDP versus the BCHP, respectively. In general, when simulating the LDP, neurovascular structures tend to be closer to the K-w when compared with the BCHP.

The mean percentage of subscapular muscle height from its superior border to the K-w was 53.03%. In 12 out of 13 shoulders, the portal was established transubscapularly. In the remaining one, the K-w was set 2 mm below the inferior border of the subscapular muscle.

In 252 out of the 260 measurements performed (99.26%), the intraclass correlation coefficient was below 0.15. In those 8 cases in which the coefficient was higher, it corresponded to very short measurements on the order of few millimeters. All the frequencies are summarized in Table 1.

DISCUSSION

Ilahi et al.[3] have recently remarked on the importance on the angle of insertion of bone anchors in the glenoid rim. This has given a new impulse to the idea of approaching the labrum detachment through the trans-subscapular portals. They not only support a more orthogonal fixation but also showed that this is much more relevant in the anteroinferior quadrant. Roth et al.[4] showed that this significantly lower performance of anchors when placed in this aspect of the labrum is the consequence of a thinner cortical thickness. Portals at about the 5 o'clock position were described in the mid-90s[5,6] in cadaveric and clinical settings. They showed that these portals were riskless, if their surgical procedures and maneuvers were followed. They used an in-out and an out-in technique, respectively. Although Davidson and Tibone[5] used the lateral decubitus in both aspects of their study, Resch et al.[6] performed the arthroscopies in the BCHP while applying axial traction. When they dissected the cadavers, they tried to reproduce the same position as in the clinical situation. Based on their own anatomic studies, the portal was established about 2 cm below the palpable coracoid tip to avoid musculocutaneous nerve lesions. In our study, the musculocutaneous nerve could be seen as close as 22.6 mm caudal to the coracoid process in 1 case. Therefore, there exists a high risk of injury to the nerve. Actually, the nerve was injured when performing the portal in 2 out of 13 of our specimens. A few years later, controversy erupted when Pearsall et al.[7] sounded the alert about the possible dangers of using these portals routinely. The consequences could be humeral head chondral lesions when performing an inside-outside technique and cephalic vein ruptures when establishing an outside-inside anteroinferior portal. The aforementioned was also supported by Lo et al.[8] when they recently tested the portal with an outside-inside method. We observed that the relationship to the deltopectoral groove and therefore to the cephalic vein and the deltoid branch of the thoracoacromial artery varied from medial to lateral in different shoulders. This, which was in concordance with Pearsall et al.,[7] could partially be a consequence of variability in the glenoid anteversion seen in the population.[9]

Although more perpendicular anchoring in the glenoid rim can be better achieved from the transubscapular portals than from more superior portals, none of the authors that advocate the use of transmuscular approaches did it completely orthogonally. Therefore, the theoretical advantages advised by Ilahi et al.[3] could not be fully taken advantage of by these transubscapular approaches. They also showed that as little as 20° of superior deviation in anchoring considerably altered strength fixation. A higher deviation only weak-

TABLE 1. *Statistic Results*

	Mean	SD	Minim	Maxim	Percentiles 25	50	75
AN LD	19.984	7.476	4.345	35.900	15.835	21.15	23.68
AN BCH	25.741	7.532	7.980	34.955	20.757	25.54	32.207
MN LD	13.271	9.897	0	27.610	5.195	13.165	24.097
MN BCH	17.687	11.078	0	33.040	6.285	20.495	28.09
AC LD	21.832	10.931	5.550	40.975	13.357	19.6	31.635
AC BCH	24.242	12.398	2.935	40.255	13.625	21.165	37.01
PC LD	23.812	9.464	5.870	39.500	14.88	25.845	30.68
PC BCH	26.251	9.154	13.080	45.700	19.457	25.99	31.977
SSA LD	35.546	13.878	27.85	55.010	29.422	35.045	45.922
SSA BCH	34.073	13.125	17.915	47.945	28.830	38.29	42.305
CV LD	11.405	7.491	4.335	34.275	7.315	9.93	13.252
CV BCH	10.031	7.479	2.935	29.920	4.795	8.48	11.022
DA LD	8.978	6.451	2.400	28.495	6.107	7.335	9.060
DA BCH	8.005	6.714	2.070	26.335	3.150	6.865	9.727

NOTE. Statistical results corresponding to the distances from the K-w to the studied anatomic structures. All data are expressed in millimeters. Because of the small sample number and that frequently the variables were not adjusted to a normal distribution, medians and quartiles were used with the Wilcoxon signed rank test to compare the measurements in both positions.

Abbreviations: SD, standard deviation; Minim, minimum; Maxim, maximum; AN LD, axillary nerve lateral decubitus; AN BCH, axillary nerve beach chair; MN LD, musculocutaneous nerve lateral decubitus; MN BCH, musculocutaneous nerve beach chair; AC LD, anterior circumflex artery lateral decubitus; AC BCH, anterior circumflex artery beach chair; PC LD, posterior circumflex artery lateral decubitus; PC BCH, posterior circumflex artery beach chair; SSA LD, subscapular artery lateral decubitus; SSA BCH, subscapular artery beach chair; CV LD, cephalic vein lateral decubitus; CV BCH, cephalic vein beach chair; DA LD, deltoid branch of the thoracoacromial artery lateral decubitus; DA BCH, deltoid branch of the thoracoacromial artery beach chair.

ened fixation strength slightly more. Thus, we studied the anatomic relationships when the portal and bone penetration is strictly performed orthogonally.

It is also known that the importance of anchor fixation is almost limited to the healing tissue period. This includes the first 3 or 4 weeks when the patients are usually immobilized in adduction and internal rotation. The importance of long-lasting anchoring strength should then be relativized.

As in most cadaveric studies, extensive dissection of the surrounding tissue was necessary to properly measure distances and relationships between the portal and neurovascular structures and landmarks. This could evidently alter the natural positions of these elements. A technique that distorts the normal anatomy as little as possible when approaching and dissecting can more reliably show the distances and safe zones[10] surrounding the 5 o'clock portal.

There were 2 obvious limitations to the present study. Besides the small sample number, the second and most important limitation is related to the fact that we did not test the transubscapular portal in different positions. Nevertheless, it has been shown that different positions do not significantly alter the relationship of the neurovascular structures with respect to this portal, unless the shoulder is 90° abducted.[5]

Despite these limitations, we think that we have provided a better understanding of this controversial arthroscopic portal. We studied as many of the structures as possible from an intra-articular perspective to minimally alter the normal anatomic relationships. We used a model that reproduced the two positions most widely used in shoulder arthroscopy. We also made the portal in a manner that simplified its establishment in a strict orthogonal position. This was done to observe what structures were threatened when a strictly orthogonal approach to the glenoid rim with no specific maneuvers and arm-position manipulations is performed. Therefore, clinically speaking, we do not recommend performing a transubscapular portal in routine shoulder arthroscopy in light of these findings and considering the good results reported with the usual superior-anterior portals.

CONCLUSIONS

This study showed the risk of establishing a transubscapular portal made orthogonally to the glenoid rim, both in the LDP and BCHP. The musculocutaneous nerve and the cephalic vein are 2 of the neurovascular structures more prone to being injured. In general, the neurovascular structures are at higher risk

when performing the portal in the LDP than in the BCHP. Even though establishing an anteroinferior portal would allow inserting screw-in type fixation devices more orthogonally, this study showed the risk of performing a transubscapular portal in either technique.

REFERENCES

1. Bankart ASB. The pathology and treatment of recurrent dislocation of the shoulder joint. *Br J Surg* 1938;26:23-29.
2. Wolf EM. Anterior portals in shoulder arthroscopy. *Arthroscopy* 1989;5:201-208.
3. Ilahi OA, Al-Fahl T, Bahrani H, Luo ZP. Glenoid suture anchor fixation strength: Effect of insertion angle. *Arthroscopy* 2004;20:609-613.
4. Roth CA, Bartolozzi AR, Ciccotti MG, et al. Failure properties of suture anchors in the glenoid and the effects of cortical thickness. *Arthroscopy* 1998;14:186-191.
5. Davidson PA, Tibone JE. Anterior-inferior (5 o'clock) portal for shoulder arthroscopy. *Arthroscopy* 1995;11:519-525.
6. Resch H, Wykypiel HF, Maurer H, Wambacher M. The antero-inferior (transmuscular) approach for arthroscopic repair of the Bankart lesion: An anatomic and clinical study. *Arthroscopy* 1996;12:309-319; discussion 320-322.
7. Pearsall AW 4th, Holovacs TF, Speer KP. The low anterior five-o'clock portal during arthroscopic shoulder surgery performed in the beach-chair position. *Am J Sports Med* 1999;27:571-574.
8. Lo IK, Lind CC, Burkhart SS. Glenohumeral arthroscopy portals established using an outside-in technique: Neurovascular anatomy at risk. *Arthroscopy* 2004;20:596-602.
9. Nyffeler RW, Jost B, Pfirrmann CW, Gerber C. Measurement of glenoid version: Conventional radiographs versus computed tomography scans. *J Shoulder Elbow Surg* 2003;12:493-496.
10. Price MR, Tillett ED, Acland RD, Nettleton GS. Determining the relationship of the axillary nerve to the shoulder joint capsule from an arthroscopic perspective. *J Bone Joint Surg Am* 2004;86:2135-2142.