

See discussions, stats, and author profiles for this publication at: <https://www.researchgate.net/publication/5897942>

# Symptomatic ring-shaped medial meniscus

ARTICLE *in* CLINICAL ANATOMY · NOVEMBER 2007

Impact Factor: 1.33 · DOI: 10.1002/ca.20516 · Source: PubMed

---

CITATIONS

5

---

READS

59

2 AUTHORS, INCLUDING:



[Juan Carlos Monllau](#)

Consorti MAR Parc de Salut de Barcelona

**125** PUBLICATIONS **767** CITATIONS

SEE PROFILE

## COMPENDIUM OF ANATOMICAL VARIANTS

# Symptomatic Ring-Shaped Medial Meniscus

ALBERT GINÉS-CESPEDOSA\* AND JOAN C. MONLLAU

Department of Orthopaedics, Knee Unit, IMAS-Hospital del Mar and Hospital de l'Esperança, Universitat Autònoma de Barcelona, Barcelona, Spain

## INTRODUCTION

Meniscal variations have increasingly been reported in medical literature. These anomalies mainly appear in the lateral side of the knee (Arnold et al., 2000). However, meniscal variations, such as discoid meniscus and hypoplasia, can also be found in the medial side (Cave and Staples, 1941; Min et al., 2001; Yañez-Acevedo, 2001; Tachibana et al., 2003; Monllau et al., 2006).

The purpose of this study is to report the finding of a ring-shaped medial meniscus.

## CASE

A 27-year-old woman presented with a 6-month-history of her right knee locking as she walked. On physical examination, the knee appeared minimally swollen and the patient complained about medial knee pain. Both McMurray and Apley meniscal tests were slightly positive for the medial meniscus. MRI showed a linear image at the posterior horn of the medial meniscus.

Because of the persistence of symptoms after a course of nonoperative treatment, arthroscopic surgery was indicated. At surgery, a ring-shaped medial meniscus with a cleavage tear at the posterior horn was found (Fig. 1). So a partial meniscectomy to a stable rim was performed.

## DISCUSSION

A lateral discoid meniscus results from a developmental anomaly. It is an uncommon finding except in oriental populations (20%) (Seong and Park, 1992). Watanabe described three types of lateral discoid meniscus (Watanabe et al., 1979). Most recently, a fourth type, consisting in a ring-shaped meniscus, has also been proposed (Monllau et al., 1998; Arnold et al., 2000; Fujikawa et al., 2002). A ring-shaped meniscus is a variant characterized by a ring-shaped morphology with a normal posterior tibial attachment (Monllau et al., 2006).

As far as we know, there has been no previous description of a **true** medial ring-shaped meniscus. Watson-Jones (1930) and Basmajian (1952) had previously reported descriptions of what appeared to be a medial ring-shaped meniscus. However, the authors doubted whether their findings were a congenital abnormality or, more likely, an old unreduced bucket-handle medial meniscus tear.

Ring-shaped menisci have unexpectedly been found in asymptomatic individuals. Associated intraarticular anomalies, which may accompany them, do not seem to bear any relation to patients' symptoms either (Kim et al., 1998). Patient's complaints are usually related to a pathologic alteration of this congenital malformation, like a tear (Kim et al., 2006) or a cyst (Arnold et al., 2000). Since the ability of the meniscus to exert its mechanical functions depends on its morphology, as well as the integrity of the collagen network, it may be assumed that any change in this condition could increase its mechanical deformation predisposing it to injury.

The congenital origin of all these variations is widely accepted (Soren, 1985; Monllau et al., 1998; Kim et al., 2006). Two facts might contribute to support this theory. Firstly, there is the association of the discoid meniscus with other intraarticular anomalies which originated in the same embryogenic period (Min et al., 2001). Secondly, it is known that in some primates (Catarrhini, Hylobates, and Gorilla) the lateral meniscus has a circular shape (Soren, 1985; Le Minor, 1990). This fact seems to be related to the high rotational ability of the knee (Basmajian, 1952). Therefore, the ring-shaped meniscus in human beings may be a regression in embryological development (Basmajian, 1952; Soren, 1985).

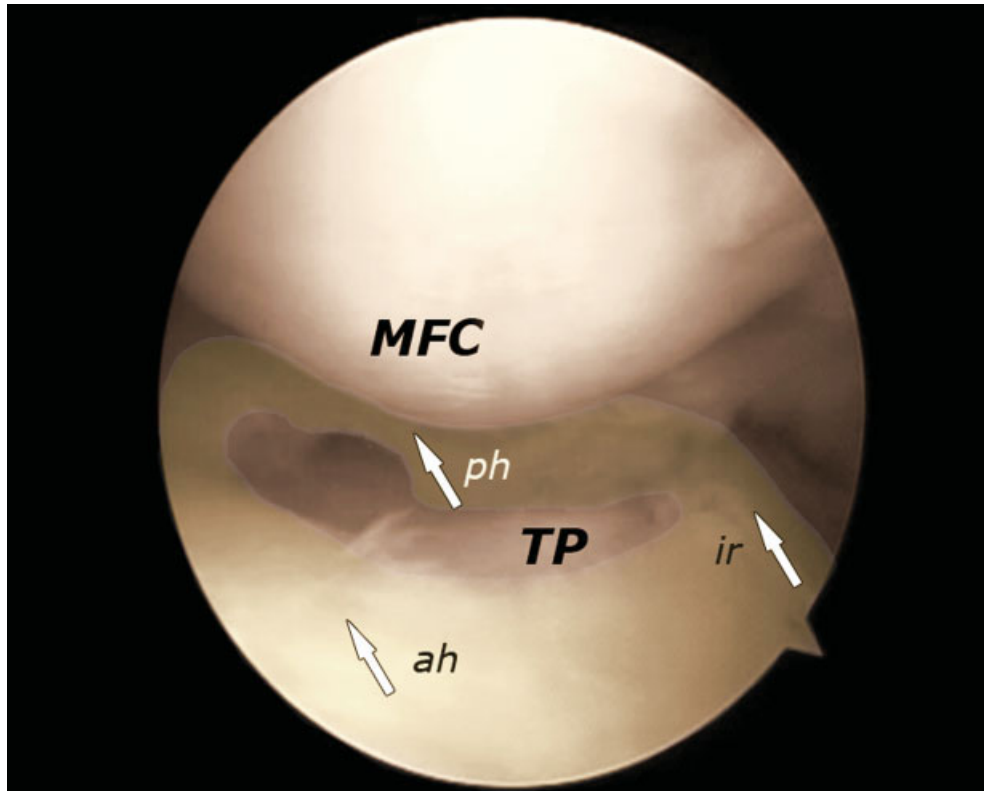
## REFERENCES

- Arnold MP, Van Kampen A. 2000. Symptomatic ring-shaped lateral meniscus. *Arthroscopy* 16:852–854.
- Basmajian JV. 1952. A ring-shaped medial semilunar cartilage. *J Bone Joint Surg Br* 34:638–639.
- Cave EF, Staples OS. 1941. Congenital discoid meniscus: A cause of internal derangement of the knee. *Am J Surg* 54:371.

\*Correspondence to: Albert Ginés-Cespedosa, Department of Orthopaedics, Knee Unit, IMAS-Hospital de l'Esperança, Avda Sant Josep de la Muntanya, 12, 08024 Barcelona, Spain.  
E-mail: 93577@imas.imim.es

Received 22 June 2007; Revised 27 August 2007; Accepted 4 September 2007

Published online 22 October 2007 in Wiley InterScience (www.interscience.wiley.com). DOI 10.1002/ca.20516



**Fig. 1.** Arthroscopic view of the ring-shaped medial meniscus. The image has been highlighted. MFC, medial femoral condyle; TP, tibial plateau; ah, anterior horn; ph, posterior horn; ir, inner rim. [Color figure can be viewed in the online issue, which is available at [www.interscience.wiley.com](http://www.interscience.wiley.com).]

- Fujikawa A, Amma H, Ukegawa Y, Tamura T, Naoi Y. 2002. MR imaging of meniscal malformations of the knee mimicking displaced bucket-handle tear. *Skeletal Radiol* 31:292-295.
- Kim SJ, Lee YT, Kim DW. 1998. Intraarticular anatomic variants associated with discoid meniscus in Koreans. *Clin Orthop Relat Res* 356:202-207.
- Kim YG, Ihn JC, Park SK, Kyung HS. 2006. An arthroscopic analysis of lateral meniscal variants and a comparison with MRI findings. *Knee Surg Sports Traumatol Arthrosc* 14:20-26.
- Le Minor JM. 1990. Comparative morphology of the lateral meniscus of the knee in primates. *J Anat* 170:161-171.
- Min BH, Ha HK, Khang SY. 2001. Medial discoid meniscus completely coalesced with the anterior cruciate ligament. *Arthroscopy* 17:E27.
- Monllau JC, Leon A, Cugat R, Ballester J. 1998. Ring-shaped lateral meniscus. *Arthroscopy* 14:502-504.
- Monllau JC, Gonzalez G, Puig L, Caceyes E. 2006. Bilateral hypoplasia of medial meniscus. *Knee Surg Sports Traumatol Arthrosc* 14:112-113.
- Seong SC, Park MJ. 1992. Analysis of the discoid meniscus in Koreans. *Orthopedics* 15:61-65.
- Soren A. 1985. On the etiology of congenital malformation of the meniscus. *Arch Orthop Trauma Surg* 104:283-288.
- Tachibana Y, Yamazaki Y, Ninomiya S. 2003. Discoid medial meniscus. *Arthroscopy* 19:E12-E18.
- Watanabe M, Takeda S, Ikeuchi H. 1979. *Atlas of Arthroscopy*. 3rd Ed. Tokyo: Igaku-Shoin. p 87-91.
- Watson-Jones R. 1930. Specimen of internal semilunar cartilage as a complete disc. *Proc R Soc Med* 23:1588-1589.
- Yañez-Acevedo A. 2001. Bilateral discoid lateral menisci and unilateral discoid medial menisci. *Arthroscopy* 17:772-775.