Capsulodesis Versus Bone Trough Technique in Lateral Meniscal Allograft Transplantation: Graft Extrusion and Functional Results

Angel Masferrer-Pino, M.D., Joan C. Monllau, M.D., Ph.D., Maximiliano Ibáñez, M.D., Juan I. Erquicia, M.D., Xavier Pelfort, M.D., Ph.D., and Pablo E. Gelber, M.D., Ph.D.

Purpose: To compare the radiographic results (in terms of graft extrusion) and the functional results of lateral meniscus allograft transplantations (MAT) performed with a bony fixation technique or with a soft tissue fixation technique after capsulodesis. **Methods:** A prospective series of 29 consecutive lateral MAT was analyzed. The inclusion criterion for MAT was lateral joint line pain due to a previous meniscectomy. Malalignment, patients who had an Ahlback grade greater than II, and patients with a body mass index over 30 were considered as the exclusion criterion to prevent confounding results. Fifteen of the grafts were fixed with a bony fixation technique (group A). The remaining 14 cases (group B) were fixed with sutures through bone tunnels after lateral capsular fixation (capsulodesis). All patients were studied with magnetic resonance imaging to determine the degree of meniscal extrusion at an average of 18 months of surgery (range, 12-48 months). Meniscal extrusion was measured on coronal magnetic resonance imaging. To standardize the results, the percentage of meniscus extruded for each group was also calculated and compared. The functional results were analyzed by means of standard knee scores (Lysholm, Tegner, and visual analog scale). **Results:** If we consider the first 4 cases of group B as the learning curve of the new technique, we observe that group A had 8 cases (53.3%) of major extrusion, whereas group B had 1 case (7.1%) ($P = .02$). When comparing the degree of meniscal extrusion with the type of fixation employed, an even lower percentage of extruded menisci was found in group B ($P = .01$). The final follow-up Lysholm score in group A was 94.33 ± 5.96 ($P < .001$) and 91.43 ± 6.19 ($P < .001$) in group B. The median follow-up Tegner score significantly improved from 4 (range, 2-5) to 7 (range, 6-9) in group A ($P < .001$) and from 4 (range, 3-5) to 7 (range, 6-8) in group B ($P < .001$). The average visual analog scale score dropped down 5.87 and 7.29 points in groups A and B, respectively ($P < .001$). The Knee Injury and Osteoarthritis Outcome Score improved from 51.98 ± 2.84 to 90.88 ± 7.53 in group A ($P < .001$) and from 50.44 ± 2.32 to 92.01 ± 6.71 in group B ($P < .001$). Patient satisfaction with regard to the procedure stood at a mean of 3.6 ± 0.2 points out of a maximum of 4 in group A and 3.8 ± 0.4 in group B. There were no complications in this series. **Conclusions:** The capsulodesis technique in lateral MAT proved not to be statistically different at decreasing the degree of meniscal extrusion with respect to the bone-bridge fixation. If the first 4 cases using the new capsulodesis technique had not included in the results, the capsulodesis technique would have effectively presented better results relative to the degree of meniscal extrusion compared with the bone-bridge fixation technique. In addition, the functional results were similar. **Level of Evidence:** Level II, prospective comparative study.

With the aim of trying to replace lost tissue as well as to prevent progressive deterioration of the joint, meniscal allograft transplantation (MAT) was introduced into clinical practice in the mid-1980s.[1] MAT has shown favorable clinical results in terms of pain relief and functional improvement on a short- and medium-term basis.[2] Over the years, several surgical soft-tissue and bone fixation techniques have been described to fix the graft. However, the best treatment option remains unclear because no significant clinical differences have been found between them.[2] A tendency to a radial displacement of the transplanted menisci that exceeded the tibial plateau, the so-called extrusion, was found in most of the published series.[3] From a biomechanical standpoint, an extruded meniscus results in decreased

From the ICATME, Hospital Universitari Dexeus—Universitat Autònoma de Barcelona (A.M-P., J.C.M., M.I., J.I.E., X.P., P.E.G.); Department of Orthopaedic Surgery, Hospital del Mar—Universitat Autònoma de Barcelona (J.C.M.), Barcelona; Department of Orthopaedic Surgery, Consorci Sanitari de l'Anoia (X.P.), Igualada; and Department of Orthopaedic Surgery, Hospital de la Sta Creu I Sant Pau (P.E.G.), Barcelona, Spain.

The authors report that they have no conflicts of interest in the authorship and publication of this article. Full ICMJE author disclosure forms are available for this article online, as supplementary material.

Received June 26, 2017; accepted January 7, 2018.

Address correspondence to Angel Masferrer-Pino, M.D., Department of Orthopedic Surgery and Traumatology, ICATME, Hospital Universitari Dexeus—Universitat Autònoma de Barcelona, Sabino Arana, 5-19, 08028, Barcelona, Spain. E-mail: angel.masferrer@gmail.com

© 2018 by the Arthroscopy Association of North America

0749-8063/17753/$36.00

https://doi.org/10.1016/j.arthro.2018.01.017

resistance to hoop strain. Thus, it cannot fulfill its biomechanical properties. Extrusion is an intriguing phenomenon that is usually identified shortly after transplantation and seems to be stable over time.[4] Early studies have shown that bony fixation is biomechanically superior[5] and so it can better prevent extrusion. In addition, more recent clinical reports have also shown more extrusion when the allografts are only fixed to soft tissue.[6,7] However, it has not shown to have any clinical relevance. Although the final significance of extrusion is unknown, the anomalous position of those grafts causes concern among surgeons. Therefore, several strategies have been developed over recent years to limit or prevent MAT extrusion.

The purpose of this study was to compare the radiographic results (in terms of graft extrusion) and the functional results of lateral MAT performed with a bony fixation technique or with a soft tissue fixation technique after capsulodesis. The first hypothesis was that capsular fixation would reduce the postoperative degree of allograft extrusion as much as the bony fixation technique. The second hypothesis was that MAT fixed with a previous capsulodesis would have similar functional results to those obtained with a bony fixation technique.

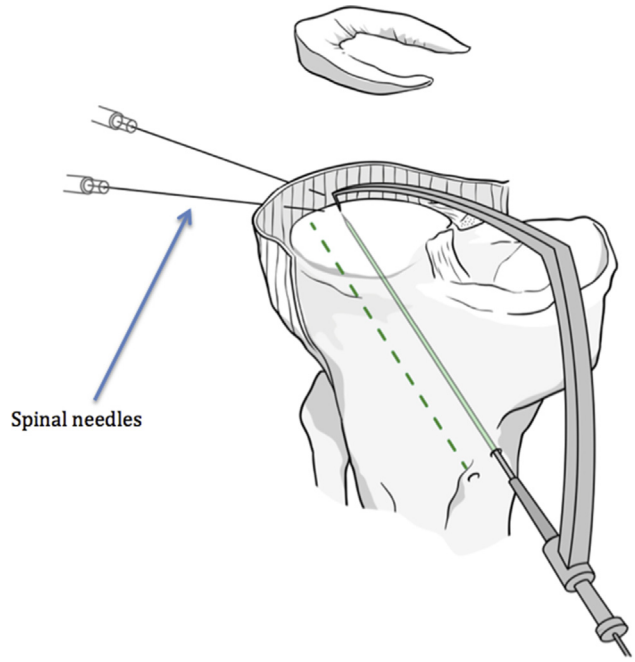

Fig 1. Right knee, anteromedial view. Lateral capsulodesis tunnels placement using the anterior cruciate ligament pin guide through the anteromedial portal.

Methods

A prospective, randomized clinical trial was designed based on the CONSORT guidelines. The study protocol was approved by the local ethical committee for clinical research, and informed consent was obtained from all patients. Twenty-nine consecutive patients were operated on with a lateral MAT between 2011 and 2015. The patients were randomly assigned with permuted blocks to the bony fixation group (group A) or the capsulodesis group (group B). All the surgical procedures were performed by the senior author (J.C.M.).

The inclusion criterion for MAT was lateral joint line pain due to a previous meniscectomy (total, subtotal, or partial). Although no relationship between malalignment and meniscal extrusion has been established, malalignment was considered an exclusion criterion to prevent confounding results. We consider genu varus and genu valgo above 5° with respect to the normal axis as malalignment. Patients who had an Ahlback[8] grade greater than II were also excluded. Moreover, patients with a body mass index over 30 were excluded in this series.

All the functional and radiographic evaluations were performed by 2 independent observers (orthopaedic surgeons). With regard to the functional evaluation, the observers were blinded to the different types of allograft fixations used.

Surgical Technique

Fresh-frozen (−80°C), nonirradiated, nonantigen matched meniscal allografts were used in this series. The allografts were supplied by an authorized local tissue bank. Allograft sizing was performed based on the method described by Pollard et al.[9] The measurements were also matched with the donor's morphometric dimensions (weight and size).

The surgical technique was completely arthroscopic and varied depending on the group. Both techniques have been previously described in detail.[6,10] The recipient bed preparation was similar in all cases. The remains of the host meniscus were assessed and revitalized using a combination of arthroscopic shaving and radiofrequency to promote healing.

- Group A: A bone bridge-in-slot technique was used to better maintain the native distance between the horns and reduce the risk of incorrect placement. The bone-bridge procedure requires the creation of a trough in the lateral tibial plateau. Differently to the dovetail technique where the bone trough and tibial slot have both a semitrapezoidal shape,[11] the shape of the bone trough in this series was quadrangular in all cases. To get a perfect match between the trough and the bone-bridge graft, a set of instruments was used (Meniscal Transplant Set. Surgival, Valencia, Spain). A low lateral portal, adjacent to the patellar tendon and aligned with the position of the planned trough, is created. Depending on the knee size, a 7 or 8 mm cannulated drill and rasp was used until a final 7 to 8 mm wide and 10 mm deep box was obtained. The bone graft was placed in its bed simply by sliding it through the previously enlarged anterolateral portal.

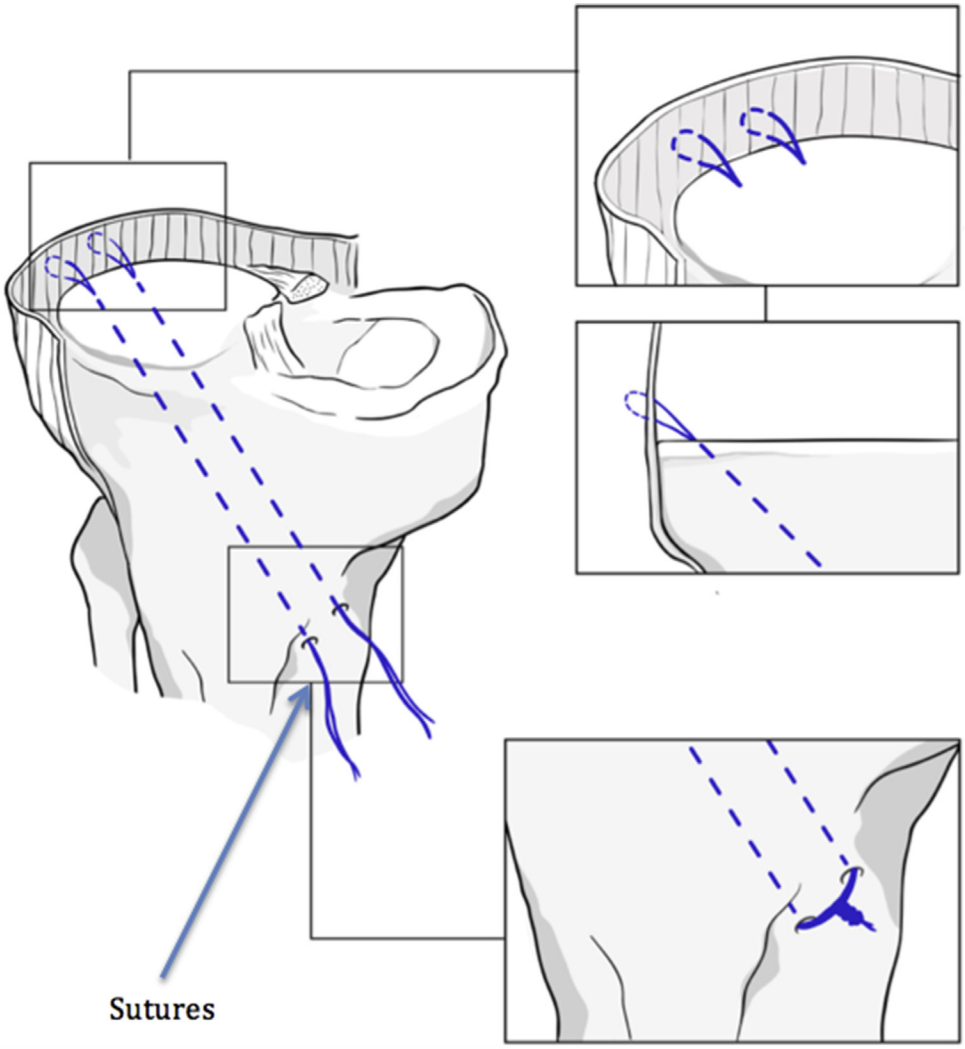

Fig 2. Capsular fixation suture passed through each transtibial tunnel and tied to each other on the medial cortex fixing the capsule to the tibial plateau.

A traction suture placed on the meniscal graft, just anterior to the level of the popliteal hiatus area, helps the surgeon to accommodate the graft in place. The meniscus allograft is then fixed to the rim by 8 to 10 nonabsorbable vertical mattress sutures. All-inside sutures (FasT-Fix, Smith & Nephew, Andover, MA) are used to secure the most posterior part of the graft to minimize the risk of injury to neurovascular structures. An inside-out technique (Zone Specific II Meniscal Repair System, Conmed, Largo, FL) or alternatively an outside-in technique, performed with the help of 18 gauge spinal needles, was used for the anterior half of the meniscal graft.

- Group B: The redundant or loose lateral capsule was identified and any marginal osteophyte on the lateral edge of the tibial plateau was removed with the help of a motorized burr. Two 2.4-mm tunnels placed 10 mm apart were then drilled from the anteromedial tibial cortex in an oblique direction ending at the edge of the lateral plateau where the capsule is most displaced (Fig 1). It was done with the help of a regular tibial anterior cruciate ligament guide (Pinn-ACL Guide, ConMed). Two sutures were then passed through the tunnels using a suture passer. The capsule and meniscal remnants were captured using spinal needles loaded with number 2 polydioxanone sutures using an outside-in technique. These shuttle sutures were substituted by high-strength sutures and recovered through each tibial tunnel. Once captured, the capsule is secured to the lateral tibial plateau (capsulodesis). Finally, the 2 limbs were tied to each other on the medial tibial cortex (Fig 2). Once the capsulodesis has been performed, two 6-mm bone tunnels were drilled directly at the anatomic sites of the meniscal insertion (i.e., at the anterior and posterior horns). After enlarging the anterolateral portal, the posterior-horn suture as well as an additional vertical suture placed at the posterolateral

Fig 3. Magnetic resonance image showing the method used for meniscal extrusion calculation. Distance ab, meniscal extrusion in mm; ab/ac × 100, percentage of meniscal extrusion.

corner of the graft was used to pull and accommodate the meniscal allograft in the right position as it was being introduced into the joint. Then, the graft was fixed to the rim by combining an all-inside and an inside-out or outside-in technique, respectively, depending on the area of the meniscus as described earlier on. At the end of the procedure, the sutures placed at the anterior and posterior horns were tied together over the tibial cortex.

Rehabilitation

Both groups followed the same protocol. It included proprioceptive weight-bearing with a knee immobilizer at full extension for 2 weeks postoperatively. Then, weight-bearing was progressively initiated until total weight-bearing was reached at 4 to 6 weeks from the surgery. Range of motion was limited to 60° the first 2 weeks, to 90° by week 4, progressing to full range of motion by week 6, postoperatively. Patients returned to a normal workload by the fourth month after surgery.

Magnetic Resonance Imaging Evaluation

To examine the degree of meniscal extrusion, all 29 patients underwent a magnetic resonance imaging (MRI) examination on the operated knee joint with full knee extension in the supine position before surgery and between 36 and 48 months of follow-up. All studies were performed with a 1.5-T superconducting magnet (Prestige 2T, Elscint, Haifa, Israel) using a knee-specific circular coil. A positioning device for the ankle was used to ensure uniformity. The standard knee protocol for each patient consisted of this sequence: axial fast spin echo T2-weighted with fat saturation (repetition time [TR], 2,300 ms; echo time [TE], 30 ms; flip angle [FA], 90°; slice thickness [ST], 3 mm; field of view [FOV], 20 cm), coronal fast spin echo intermediate-weighted (TR, 2,500 ms; TE, 30 ms; FA, 90°; ST, 4 mm; FOV, 18 cm), sagittal spin echo intermediate-weighted (TR, 700 ms; TE, 14 ms; FA, 90°; ST, 4 mm; FOV, 18 cm), and sagittal fast spin echo T2-weighted with fat saturation (TR, 2,500 ms; TE, 85 ms; FA, 90°; ST, 4 mm; FOV, 18 cm).

The MRI scans were evaluated twice, at an interval of 2 weeks, and carried out by 2 of the authors with experience in knee MRI. The averages of these 2 measurements were employed in the analysis. The PACS workstation (Centricity Enterprise Web V3.0, General Electric Healthcare, Milwaukee, WI) was used for the study.

As in previous investigations,[12] the graft position was evaluated on coronal images, where extrusion was maximum, with the use of an MRI-generated scale on each image. Those coronal images usually coincided with the level of the corresponding collateral ligaments.[13] Measurement was performed by first drawing 2 lines. The first one was a vertical line that intersected the peripheral margin of the lateral tibial plateau at the point of transition from horizontal to vertical. Next, a perpendicular line was drawn from the outer margin of the meniscus to the former line. The perpendicular line's length in millimeters was defined as the amount of meniscal extrusion.[12,14] According to Costa et al.,[14] when the graft showed less than 3 mm of radial displacement, it was considered minor extrusion. Conversely, when it exhibited 3 or more millimeters of subluxation, it was defined as major extrusion. Extrusion as a percentage of meniscus size was also calculated to standardize the results (Fig 3). This was done by dividing the quantity of meniscal extrusion by the total width of the meniscus as measured in the same MRI scan.[12] Major and minor extrusion as well as the observed percentage of extruded meniscal tissue was compared in groups A and B.

Functional evaluation at the final follow-up included the Lysholm score as well as the Tegner score and Knee Injury and Osteoarthritis Outcome Score (KOOS). A 10-point visual analog scale (VAS) for pain was also used. The reported results were compared between groups. Patient satisfaction was evaluated with a subjective score and graded as very satisfied (4 points), satisfied (3 points), neutral (2 points), somewhat dissatisfied (1 point), and not satisfied at all (0 points).

Statistical Analysis

Categorical variables are presented as percentages and frequencies. Continuous variables are presented as mean ± standard deviation. Interobserver agreement was analyzed using the intraclass correlation coefficient in the case of a quantitative variable.[15] The values were interpreted as slight (<0.21), fair (0.21-0.40), moderate

Table 1. Composition of Both Groups Before Surgery

Variable	Group A	Group B	Significance (*P*)
Age, yr	35.47 ± 8.50 (30.76, 40.17)	40.93 ± 7.03 (36.87, 44.99)	.86
Gender, male/female, %	60/40	71.5/28.5	.52
Lysholm	61.33 ± 9.93 (55.83, 66.83)	48.79 ± 13.90 (40.76, 56.81)	.05
Tegner	4 (2-5) (2.96, 4.64)	4 (3-5) (2.95, 4.48)	.87
Visual analog scale	7.53 ± 2.53 (5.13, 7.94)	8.21 ± 0.97 (7.65, 8.78)	.51
Rx joint space narrowing, mm	3.10 ± 1.50 (2.74, 3.64)	3.00 ± 1.20 (2.83, 4.01)	.44

NOTE. Values expressed as mean, standard deviation, and 95% confidence interval unless otherwise indicated.

(0.41-0.60), substantial (0.61-0.80), and excellent (0.81-1.00).[16] In all cases, a 95% confidence interval was calculated. The relationships between categorical variables were described with contingency tables. The inference was studied with the χ-square test or Fisher exact test depending on what corresponded. Meniscal extrusion rates and functional scores were compared between the 2 groups using Student's *t*-test given that all the variables followed normal distributions according to the skewness and kurtosis test. The sample size was based on a priori power calculations for extrusion. On the basis of a Student's *t*-test for independent data with a statistical power of 80% and an alpha error of 0.05, we calculated the patients needed in the groups to detect a minimum difference of 10% in the degree of meniscal extrusion as statistically significant, assuming a standard deviation of 3 and a maximum follow-up loss of 10%. Again, the homogeneous results obtained and the use of Fisher's exact test for comparing 2 samples led us to think that it was big enough for the purposes of this investigation.

The statistical analysis was performed using the SPSS 19 package (SPSS, Chicago, IL). Statistical significance was set at .05.

Results

The average follow-up period was 2.1 years (range, 1-4 years) and 1.5 years for the postoperative MRI (range, 1-4). No patients were lost during follow-up. The series was composed of 19 men (65.5%) and 10 women (34.5%) with a mean age of 38.2 years (range, 26-51 years). All transplantations (100%) were performed to replace the lateral meniscus. Fourteen (48.3%) MAT were performed on right knees and 15 (51.7%) on left knees. Group A consisted of 15 grafts (51.7%) that were fixed with a bony fixation technique, the bone bar-trough technique. Group B were composed of 14 grafts (48.3%) that were secured with bone tunnels at both horns and soft tissue capsular fixation after the capsulodesis was performed. Both groups were comparable in terms of age, gender, and radiographic findings as well as their functional preoperative status (Table 1), except for the preoperative Lysholm scale.

Graft Extrusion

Based on the aforementioned extrusion criteria, 17 knees (58.62%) exhibited minor graft extrusion (<3 mm) and 12 (41.38%) had major graft extrusion (>3 mm). In group A, 7 cases (46.67%) were considered minor extrusion and 8 cases (53.33%) major extrusion, whereas there were 10 (71.43%) and 4 cases (28.57%), respectively ($P = .18$), in group B (Table 2). When comparing the degree of meniscal extrusion with the type of fixation employed, a tendency toward a lower percentage of extrusion was also found in group B. In group A, this percentage was 34.40 ± 12.16, whereas 24.65 ± 15.49 observed in group B ($P = .07$) (Table 3).

The worst rate of graft extrusion in group B was seen in the first 4 cases. If these 4 cases were ignored, the obtained results would be even better as only 1 case of major extrusion would be found in group B ($P = .027$) (Table 4). When comparing the degree of meniscal extrusion with the type of fixation employed, an even lower percentage of extruded menisci was found in group B ($P = .01$) (Table 5; Fig 4).

Clinical Outcomes

With regard to the functional results assessed with the Lysholm score, an overall improvement was obtained regardless of the technique used. Starting from a Lysholm score of 61.33 ± 9.93 and 48.79 ± 13.90 in groups A and B, respectively, the final follow-up score in group A was 94.33 ± 5.96 ($P < .001$) and 91.43 ± 6.19 ($P < .001$) in group B (Fig 5A). Similarly, an

Table 2. Frequency of Graft Extrusion (All Cases)

	Minor	Major
Bony fixation	7 (46.67%)	8 (53.33%)
Capsulodesis	10 (71.43%)	4 (28.57%)
Total	17 (58.62%)	12 (41.38%)
		$P = .18$

Table 3. Frequency of Graft Extrusion (Excluding the 4 Cases of Learning Curve)

	Minor	Major
Bony fixation	7 (46.67%)	8 (53.33%)
Capsulodesis	9 (90%)	1 (10.00%)
Total	16 (64.00%)	9 (36.00%)
		$P = .027$

Table 4. Graft Extrusion Percentage (All Cases)

Group	Observations	Mean	SD
Bony fixation	15	34.40	12.16
Capsulodesis	14	24.65	15.49
P value	.07		

SD, standard deviation.

overall improvement was obtained with regard to the Tegner and VAS scores. The average Tegner score significantly improved from 4 (range, 2-5) to 7 (range, 6-9) in group A ($P < .001$) and from 4 (range, 3-5) to 7 (range, 6-8) in group B ($P < .001$) (Fig 5B). The average VAS score dropped from 7.53 ± 2.53 to 0.67 ± 1.11 in group A ($P < .001$) and from 8.21 ± 0.97 to 0.93 ± 1.00 in group B ($P < .001$), so decreased 5.87 and 7.29 points average in groups A and B, respectively (Fig 5C). The Knee Injury and Osteoarthritis Outcome Score improved from 51.98 ± 2.84 to 90.88 ± 7.53 in group A ($P < .001$) and from 50.44 ± 2.32 to 92.01 ± 6.71 in group B ($P < .001$) (Fig 5D). Finally, patient satisfaction with regard to the procedure showed an overall mean of 3.6 ± 0.2 points out of a maximum of 4 in group A and 3.8 ± 0.4 in group B. No differences were observed when the 2 groups under study were compared in any of the analyzed variables (Table 6). Finally, the intraclass correlation coefficient obtained was considered excellent (0.94; 95% confidence interval, 0.81 to 0.97). No complications were recorded in this series.

Discussion

The principal finding of the present investigation was that lateral MAT fixed with sutures through bone tunnels after a capsulodesis showed a lower percentage of extrusion than those performed with the bony fixation technique. These results could even be better (statistically significant) if the effect of the learning curve was avoided. It is likely that it may be due to the learning curve of the new technique. Although the described technique was first performed in a pilot study with cadaveric specimens and 5 patients who were not included in this series, a potentially long learning curve effect cannot be discarded. Therefore, the first hypothesis was confirmed. With regard to the functional results, they were similar in both groups. This means that both fixation techniques would give good short-term

Table 5. Graft Extrusion Percentage (Excluding the 4 Cases of Learning Curve)

Group	Observations	Mean	SD
Bony fixation	15	34.40	12.16
Capsulodesis	10	19.15	12.41
P value	.01		

SD, standard deviation.

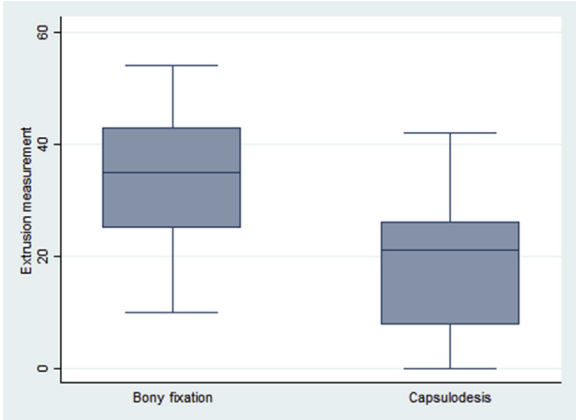

Fig 4. A lower meniscal extrusion percentage was observed in group B.

outcomes as has been shown in previously published literature. Therefore, the second hypothesis was also confirmed. Although there is a statistical difference in the outcome scores, there does not appear to be a clinical difference in the form of minimal clinically important differences.[17]

Meniscal transplants have been shown to extrude more than normal menisci.[18,19] Although the final significance of extrusion is unknown, the anomalous position of those grafts causes concern among surgeons. To avoid extrusion, a number of strategies have recently been proposed. In the current investigation, a simple, implant-free soft tissue fixation performed after a capsulodesis is compared with a fixation technique considered to be the most effective to control graft radial displacement.[6]

Several factors have been related to meniscal allograft extrusion. They are the graft fixation method, medial versus lateral, the graft size, and the donor and recipient matching being among the most prominent. Graft fixation is crucial to preventing short- and mid-term complications due to failure and altered knee kinematics. Although peripheral fixation is achieved with sutures in all of the available techniques, the fixation of meniscal horns may be achieved either by sutures through the bone or with a bone-to-bone fixation. Some studies have shown that fixation with bone plugs is better compared with graft fixation without bone plugs in terms of the restoration of the normal contact mechanics of the knee[5,20] and complications, including graft failure.[21] However, more recent investigations have shown no biomechanical differences in the mean pullout strength between the 2 fixation methods.[22] Furthermore, MAT without bone fixation has shown good and excellent results in terms of pain relief and clinical and functional outcomes,[18,23,24] including the return to sport in top level athletes.[25,26]

Meniscal extrusion was not universally investigated in MAT. However, most of the works that look for this

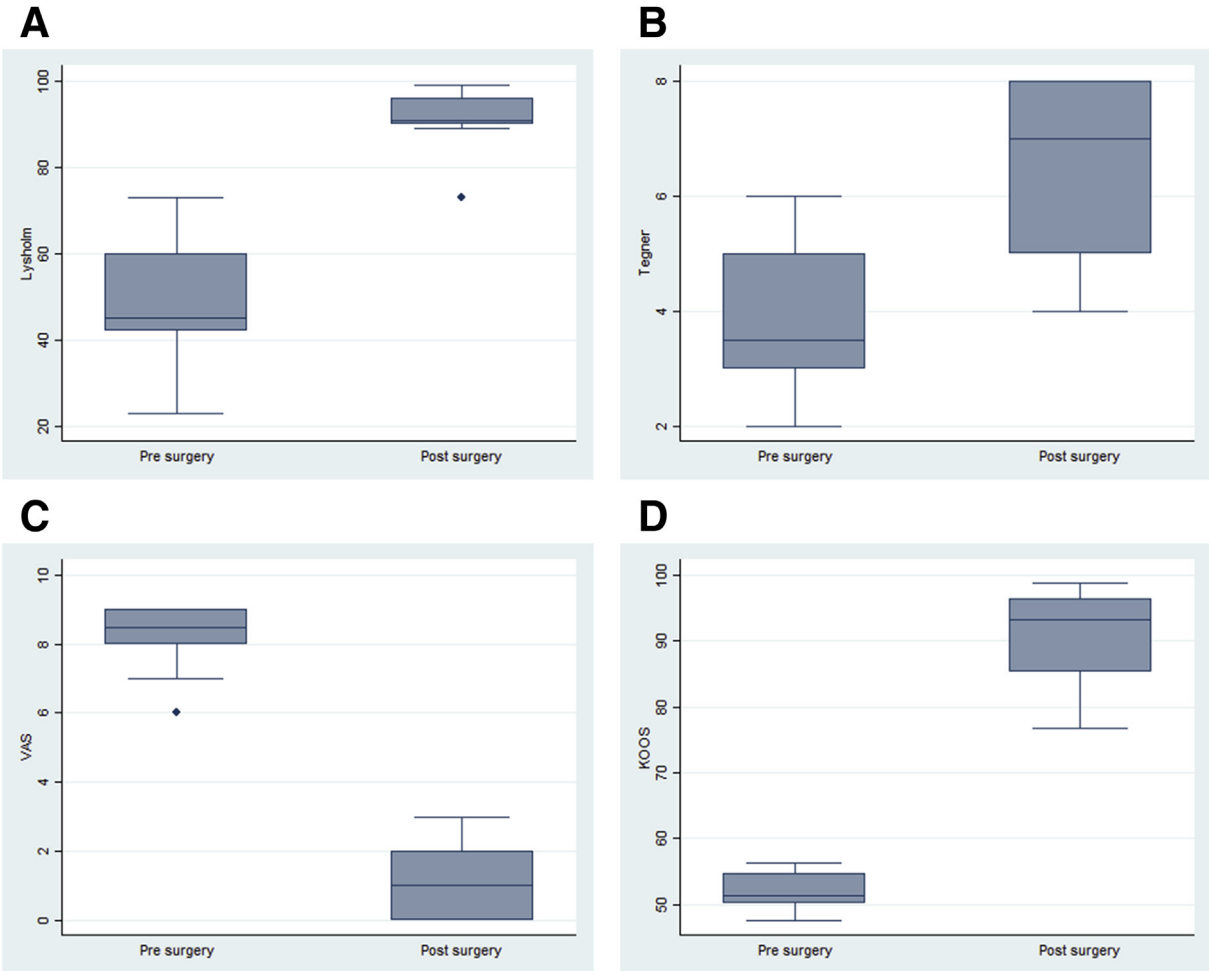

Fig 5. Overall improvement of functional scores in group B: (A) Lysholm, (B) Tegner, (C) Visual analog scale, and (D) Knee Injury and Osteoarthritis Outcome Score.

phenomenon found a high degree of graft subluxation.[4] Suture-only fixation has shown a higher degree of meniscal extrusion when compared with bone fixation. However, this was not related to worse functional or radiographic outcomes as shown in several studies comparing both methods.[6,21]

As far as we know, no study has proven that extrusion has either a deleterious effect on the joint or brings about inferior clinical outcomes after MAT. However, a radially displaced meniscus is a concern for the surgeon. Therefore, we aim to reduce or eventually avoid extrusion.

Different strategies have been proposed to decrease the degree of meniscal allograft extrusion. Jang et al.[19] reported that reducing the graft size by 5% decreases the percentage of extrusion without any adverse outcome either clinically or radiographically. Other studies have shown that the risk of graft extrusion increases as the axial plane trough angle increases. This angle can be reduced by ensuring that the bony trough starting point is not created in an excessively lateral position. Jeon et al.[27] suggested that the excision of a peripheral osteophyte larger than 2 mm in the proximal tibial plateau was

Table 6. Functional Results of Both Groups After Surgery

Variable	Group A	Group B	Significance (*P*)
Lysholm	94.33 ± 5.96 (89.83, 98.51)	91.43 ± 6.19 (86.34, 97.22)	.05
Tegner	7 (6-9) (5.97, 9.01)	7 (6-8) (5.88, 8.51)	.87
Visual analog scale	0.67 ± 1.11 (0.43, 1.21)	0.93 ± 1.00 (0.52, 1.13)	.51
KOOS	90.88 ± 7.53 (88.64, 92.01)	92.01 ± 6.71 (90.83, 96.77)	.44

NOTE. Values expressed as mean, standard deviation, and 95% confidence interval unless otherwise indicated.
KOOS, Knee Injury and Osteoarthritis Outcome Score.

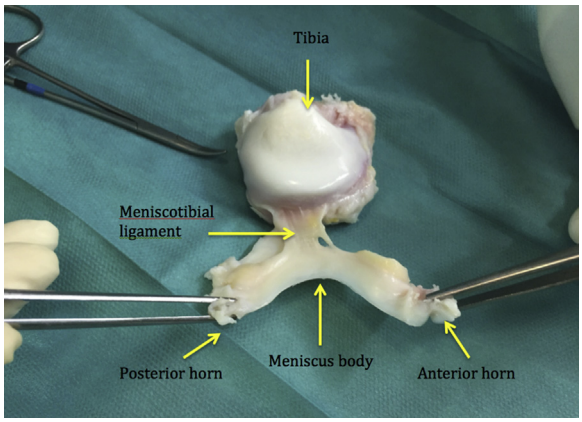

Fig 6. Gross anatomy of the lateral meniscotibial ligament during preparation of the lateral meniscus allograft. The meniscus has been detached from the roots and flipped. Note its strong attachments at both the meniscus and the tibial site.

associated with less MAT extrusion. It is also known that there are no associations between preoperative lateral subluxation of the native menisci and postoperative subluxation of meniscal transplants in patients who undergo MAT on the lateral compartment with low-grade arthritic changes.[28] Some authors have proposed stabilizing the meniscus body to the tibial plateau in an attempt to control graft extrusion. However, this maneuver may present the risk of limiting the normal mobility of the meniscus during knee motion. A recent investigation has focused on peripheral fixation, because an adequate meniscal rim is important to promoting healing and the incorporation of the graft.[29] In that sense, the reported technique explored the role that capsule fixation to the tibial plateau might play. A technical note was published by Jung et al. where the capsule was fixed to the tibial plateau.[30] However, in that technique, fixation was achieved with the help of a metal anchor. In addition, no outcomes were reported.

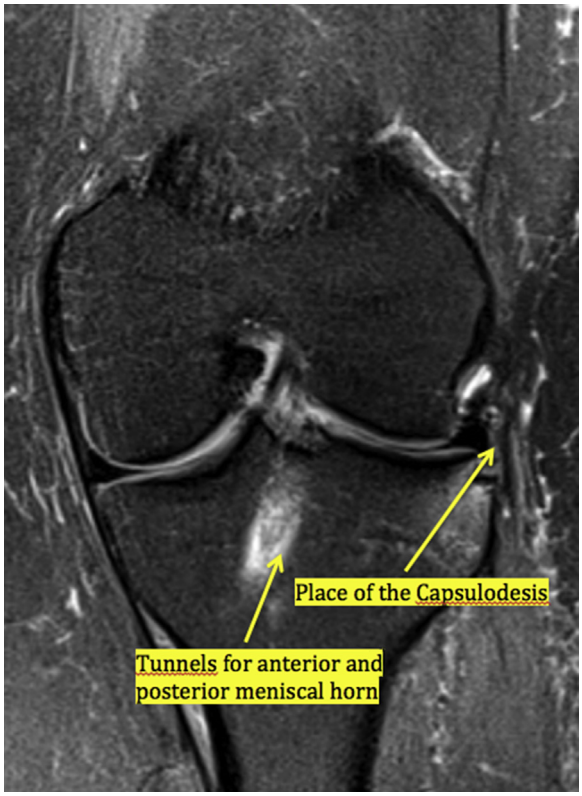

Fig 7. Magnetic resonance image at 6 months postoperatively showed the position of the mid-body of the lateral meniscus allograft and the lateral capsulodesis tibial tunnel placement.

Although the menisci root attachments have received considerable attention in recent years,[31] their peripheral attachments are much less understood, particularly in the lateral side. It is likely that lateral capsulodesis mimics the function of the meniscotibial ligament by fixing the meniscus in the articular surface[32] (Fig 6). Thereby radial displacement is limited. We are currently investigating this hypothesis (unpublished data).

Although different methods of capsular stabilization can be found in the literature, the current implant-free technique for lateral capsulodesis seems to be a valid, reliable, and an easy method to prevent MAT extrusion. It allows for versatility in terms of the number of fixation points and locations without a significant bone loss in the tibial plateau because the drill holes had only a 2.4 mm diameter. It does not interfere with subsequent MRI and there are no additional costs (Fig 7). In this early series using this technique, the lateral capsulodesis contributed to preventing graft extrusion and the results persist at the 1-year follow-up with favorable clinical outcomes. This series of capsulodesis showed one of the lowest percentages of meniscal extrusion in MAT ever reported. Longer follow-up studies are needed to confirm these results and to assess the impact that a lower degree of meniscal extrusion may have on the future of the knee involved.

Limitations

The present investigation has some limitations. Although the same techniques, which were performed by a single surgeon, have always been used in both groups, there was unavoidable learning curve in the capsulodesis group. However, if the first 4 cases of that group are not considered, the results obtained would have been even clearer. The limited sample size is another obvious limitation along with not having studied the postoperative radiographs. If we consider that the differences found may not become clinically significant in the short term, there is the possibility of a type II or beta error for outcomes because no difference was seen and the study was not powered to such. Another limitation is that the inclusion/exclusion criteria are not strict and we do not discuss concomitant procedures. In addition, of all the preoperative variables described in Table 1, including the different functional

scores, only the Lysholm score showed significant differences between the 2 groups. For this reason, we still consider both groups homogeneous. Furthermore, our clinical follow-up was only a minimum 1 year and there is a lack of intraobserver evaluation. Finally, only 2 methods of limiting extrusion were compared. So, it is unknown how efficient other methods might be.

Conclusions

The capsulodesis technique in lateral MAT proved not to be statistically different at decreasing the degree of meniscal extrusion with respect to the bone-bridge fixation. If the first 4 cases using the new capsulodesis technique had not been included in the results, the capsulodesis technique would have effectively presented better results relative to the degree of meniscal extrusion compared with the bone-bridge fixation technique. In addition, the functional results were similar.

Acknowledgment

The authors thank Julio Florentino Del Corral for assisting in the statistical analysis as well as Eric Goode for his help in correcting the manuscript.

References

1. Milachowski KA, Weismeier K, Wirth CJ. Homologous meniscus transplantation: Experimental and clinical results. *Int Orthop* 1989;13:1-11.
2. Rosso F, Bisicchia S, Bonasia DE, Amendola A. Meniscal allograft transplantation: A systematic review. *Am J Sports Med* 2015;43:998-1007.
3. Samitier G, Alentorn-Geli E, Taylor DC, et al. Meniscal allograft transplantation. Part 1: Systematic review of graft biology, graft shrinkage, graft extrusion, graft sizing, and graft fixation. *Knee Surg Sports Traumatol Arthrosc* 2015;23:310-322.
4. Lee DH, Kim TH, Lee SH, Kim CW, Kim JM, Bin S. Evaluation of meniscus allograft transplantation with serial magnetic resonance imaging during the first postoperative year: Focus on graft extrusion. *Arthroscopy* 2008;24:1115-1121.
5. Alhalki MM, Howell SM, Hull ML. How three methods for fixing a medial meniscal autograft affect tibial contact mechanics. *Am J Sports Med* 1999;27:320-328.
6. Abat F, Gelber PE, Erquicia JI, Pelfort X, Gonzalez-Lucena G, Monllau JC. Suture-only fixation technique leads to a higher degree of extrusion than bony fixation in meniscal allograft transplantation. *Am J Sports Med* 2012;40:1591-1596.
7. De Coninck T, Huysse W, Verdonk R, Verstraete K, Verdonk P. Open versus arthroscopic meniscus allograft transplantation: Magnetic resonance imaging study of meniscal radial displacement. *Arthroscopy* 2013;29:514-521.
8. Ahlbäck S, Rydberg J. X-ray classification and examination techniques in gonarthrosis. *Lakartidningen* 1980;77:2091-2093.
9. Pollard ME, Kang Q, Berg EE. Radiographic sizing for meniscal transplantation. *Arthroscopy* 1995;11:684-687.
10. Monllau JC, Ibañez M, Masferrer-Pino A, Gelber PE, Erquicia JI, Pelfort X. Lateral capsular fixation: An implant-free technique to prevent meniscal allograft. *Arthrosc Tech* 2017;6:e269-e274.
11. Lee AS, Kang RW, Kroin E, Verma NN, Cole BJ. Allograft meniscus transplantation. *Sports Med Arthrosc* 2012;20:106-114.
12. Puig L, Monllau JC, Corrales M, Pelfort X, Melendo E, Caceres E. Factors affecting meniscal extrusion: Correlation with MRI, clinical, and arthroscopic findings. *Knee Surg Sports Traumatol Arthrosc* 2006;14:394-398.
13. Sharma L, Eckstein F, Song J, et al. Relationship of meniscal damage, meniscal extrusion, malalignment, and joint laxity to subsequent cartilage loss in osteoarthritic knees. *Arthritis Rheum* 2008;58:1716-1726.
14. Costa CR, Morrison WB, Carrino JA. Medial meniscus extrusion on knee MRI: Is extent associated with severity of degeneration or type of tear? *Am J Roentgenol* 2004;183:17-23.
15. Hale CA, Fleiss JL. Interval estimation under two study designs for kappa with binary classification. *Biometrics* 1993;49:523-534.
16. Landis JR, Koch GG. The measurement of observer agreement for categorical data. *Biometrics* 1977;33:159-174.
17. Harris JD, Brand JC, Cote MP, Faucett SC, Dhawan A. Research pearls: The significance of statistics and perils of pooling. Part 1: Clinical versus statistical significance. *Arthroscopy* 2017;33:1102-1112.
18. Verdonk PC, Demurie A, Almqvist KF, Veys EM, Verbruggen G, Verdonk R. Transplantation of viable meniscal allograft. Survivorship analysis and clinical outcome of one hundred cases. *J Bone Joint Surg Am* 2005;87:715-724.
19. Jang SH, Kim JG, Ha JG, Shim JC. Reducing the size of the meniscal allograft decreases the percentage of extrusion after meniscal allograft transplantation. *Arthroscopy* 2011;27:914-922.
20. Paletta GA, Manning T, Snell E, Parker R, Bergfeld J. The effect of allograft meniscal replacement on intraarticular contact area and pressures in the human knee. *Am J Sports Med* 1997;25:692.
21. Abat F, Gelber PE, Erquicia JI, Tey M, Gonzalez-Lucena G, Monllau JC. Prospective comparative study between two different fixation techniques in meniscal allograft transplantation. *Knee Surg Sports Traumatol Arthrosc* 2013;21:1516-1522.
22. Hunt S, Kaplan K, Ishak C, Kummer FJ, Meislin R. Bone plug versus suture fixation of the posterior horn in medial meniscal allograft transplantation: A biomechanical study. *Bull NYU Hosp Jt Dis* 2008;66:22-26.
23. Alentorn-Geli E, Seijas R, García M, et al. Arthroscopic meniscal allograft transplantation without bone plugs. *Knee Surg Sports Traumatol Arthrosc* 2011;19:174-182.
24. González-Lucena G, Gelber PE, Pelfort X, Tey M, Monllau JC. Meniscal allograft transplantation without bone blocks: A 5- to 8-year follow-up of 33 patients. *Arthroscopy* 2010;26:1633-1640.
25. Alentorn-Geli E, Vazquez RS, Diaz PA, Cuscó X, Cugat R. Arthroscopic meniscal transplants in soccer players:

Outcomes at 2- to 5-year follow-up. *Clin J Sport Med* 2010;20:340-343.
26. Chalmers PN, Karas V, Sherman SL, Cole BJ. Return to high-level sports after meniscal allograft transplantation. *Arthroscopy* 2013;29:539-544.
27. Jeon B, Kim JM, Kim JM, Lee CR, Kim KA, Bin SI. An osteophyte in the tibial plateau is a risk factor for allograft extrusion after meniscus allograft transplantation. *Am J Sports Med* 2015;43:1215-1221.
28. Lee BS, Bin SI, Kim JM, Kim JH, Lim EJ. Meniscal allograft subluxations are not associated with preoperative native meniscal subluxations. *Knee Surg Sports Traumatol Arthrosc* 2017;25:200-206.
29. Matava MJ. Meniscal allograft transplantation: A systematic review. *Clin Orthop Relat Res* 2007;455:142-157.
30. Jung Y, Choi N, Victoroff BN. Arthroscopic stabilization of the lateral capsule of the knee in meniscal transplantation. *Knee Surg Sports Traumatol Arthrosc* 2011;19:189-191.
31. LaPrade CM, Ellman MB, Rasmussen MT, et al. Anatomy of the anterior root attachments of the medial and lateral menisci: A quantitative analysis. *Am J Sports Med* 2014;42:2386-2392.
32. Bezerra FS, Alves JN, Silva MAS, et al. Quantitative and descriptive analysis of the meniscotibial ligament in human corpses. *Braz J Morphol Sci* 2007;24:211-213.