The Menisco-Tibio-Popliteus-Fibular Complex: Anatomic Description of the Structures That Could Avoid Lateral Meniscal Extrusion

Angel Masferrer-Pino, M.D., Ivan Saenz-Navarro, M.D., Gonzalo Rojas, M.D., Simone Perelli, M.D., Juan Erquicia, M.D., Pablo E. Gelber, M.D., Ph.D., and Joan C. Monllau, M.D., Ph.D.

Purpose: To analyze, quantify, and redefine the anatomy of the peripheral attachments of the lateral meniscal body to further understand how the structures might play a part in preventing meniscal extrusion and how it might be applied to surgical techniques. **Methods:** Ten nonpaired fresh-frozen cadaveric knees without prior injury, a surgical history, or gross anatomic abnormality were included. There were 5 right and 5 left knees, and 50% were from male donors and 50% were from female donors. All the dissections were performed by a group of 3 experts in knee surgery (2 knee surgeons and 1 anatomy professor who oversaw the design of the dissection protocol and guided this protocol). The main peripheral structures associated with the lateral meniscus body were dissected to determine the insertion, size, thickness, and location of the lateral meniscotibial ligament (LMTL), popliteofibular ligament (PFL), and popliteomeniscal ligament (PML). The distance to various landmarks in the lateral compartment was also determined using an electronic caliper. Moreover, a histopathologic study was carried out. **Results:** The average thickness of the LMTL was 0.62 ± 0.18 mm (95% confidence interval [CI], 0.49-0.75 mm); that of the PFL-PML area was 1.05 ± 0.27 mm (95% CI, 0.85-1.24 mm). The anteroposterior distance measured 15.80 ± 4.80 mm (95% CI, 12.40-19.30 mm) for the LMTL and 10.40 ± 1.70 mm (95% CI, 9.21-11.63 mm) for the PFL-PML area. The anteroposterior distance of the whole menisco-tibio-popliteus-fibular complex (MTPFC) was 28.20 ± 4.95 mm (95% CI, 24.70-31.70 mm). The average distance from the MTPFC to the posterior horn of the lateral meniscal root was 29.30 ± 2.29 mm (95% CI, 27.60-30.90 mm), whereas that to the anterior horn was 32.00 ± 4.80 mm (95% CI, 28.60-35.50 mm). The average distance from the tibial insertion of the LMTL to the articular surface was 5.59 ± 1.22 mm (95% CI, 4.72-6.46 mm). In all the anatomic components of the knee, a consistent morphologic and histologic pattern was observed between the fibers of the LMTL, PFL, and PML and those of the lateral meniscal body, making up the proposed MTPFC. **Conclusions:** A consistent anatomic pattern has been identified between the lateral meniscal body and the LMTL, PFL, and PML, forming an interconnected complex that would seem appropriate to denominate the MTPFC. A precise study of this region and appropriate nomenclature for it could contribute to a better understanding of the mechanism of lateral meniscal injuries at this level, as well as the development of surgical techniques to treat these lesions and prevent extrusion. **Clinical Relevance:** This study contributes to the understanding of the lateral meniscal body attachments and the functions they serve. This will lead to improvements in the treatment of lesions in this region, including the development of surgical techniques.

See commentary on page 1926

From Institut Català de Traumatologia i Medicina de l'Esport (ICATME), Hospital Universitari Dexeus—Universitat Autònoma de Barcelona, Barcelona, Spain (A.M-P., S.P., J.E., P.E.G., J.C.M.); Department of Orthopaedic Surgery, Fundació Hospital Esperit Sant, Barcelona, Spain (I.S-N.); Department of Anatomy, Universitat de Barcelona, Barcelona, Spain (I.S-N.); Department of Orthopaedic Surgery, Hospital Regional de Talca, Talca, Chile (G.R.); Department of Orthopaedic Surgery, Hospital de la Santa Creu i Sant Pau, Barcelona, Spain (P.E.G.); and Department of Orthopaedic Surgery, Hospital del Mar—Universitat Autònoma de Barcelona, Barcelona, Spain (J.C.M.).

The authors report the following potential conflicts of interest or sources of funding: P.E.G. receives personal fees from ConMed, outside the submitted work. J.C.M. receives personal fees from ConMed and Smith & Nephew, outside the submitted work. Full ICMJE author disclosure forms are available for this article online, as supplementary material.

Received September 12, 2019; accepted March 1, 2020.

Address correspondence to Angel Masferrer-Pino, M.D., Department of Orthopedic Surgery and Traumatology, ICATME, Hospital Universitari Dexeus—Universitat Autònoma de Barcelona, Sabino Arana, 5-19, 08028, Barcelona, Spain. E-mail: angel.masferrer@gmail.com

© 2020 by the Arthroscopy Association of North America

0749-8063/191092/$36.00

https://doi.org/10.1016/j.arthro.2020.03.010

The anatomy of the lateral compartment of the knee, specifically the lateral meniscus and its peripheral structures, has been studied and documened.[1-4] It is widely known that the meniscus plays a crucial role in knee function and homeostasis.[5] Particularly, the lateral meniscus has greater mobility, fewer peripheral attachments, and a thinner and looser posterolateral capsule. These characteristics are probably due to the anatomy and function of the lateral compartment.[6,7] Furthermore, the existence of the popliteal hiatus causes capsule disruption and reduces vascularization in that area.[8]

Historically, there have been some differences in the way the singular anatomy of this area has been labeled and interpreted that has led to some confusion when studying it.[9-12] One of the most relevant structures is the meniscal-fibular ligament (MFL), first described in humans by Zivanovic.[13] Its existence, morphology, and histology, as well as its biomechanical characteristics, were verified later.[14,15] More recently, another structure has been described as the "meniscotibial ligament"[16] or "coronary ligament," thus further confusing the issue. It corresponds to a short and confluent ligament band that adheres peripherally to the meniscal body and serves to stabilize and maintain the meniscus in the proper position on the tibial plateau. Similarly to the MFL, the meniscotibial ligament has been defined differently in various studies over time.[17,18] It is interesting to note that the meniscofemoral ligament, coronary ligament, and popliteomeniscal ligament (PML) have received special attention in recent years.[19-22]

These meniscocapsular and meniscotibial attachments may contribute to holding the lateral menisci in place and thereby preventing extrusion. Although the final consequences of meniscal extrusion are poorly understood, every effort made to prevent radial displacement is reasonable.

Because the current definition and terminology are confusing, the purpose of this study was to analyze, quantify, and redefine the anatomy of the peripheral attachments of the lateral meniscal body to further understand how the structures might play a part in preventing meniscal extrusion and how it might be applied to surgical techniques. The first hypothesis was that the lateral meniscus would have an intricate attachment to the tibia that included the lateral meniscotibial ligament (LMTL), popliteofibular ligament (PFL), and PML, forming a combination that might be better denominated the "menisco-tibio-popliteus-fibular complex" (MTPFC). The second hypothesis was that these ligaments would have a defined anatomy (in terms of thickness and histology) and constant dynamic relation, so they would act together to fix the lateral side of the meniscus to the tibia and capsule.

Methods

Twelve nonpaired fresh-frozen cadaveric knees without prior injury, a surgical history, or gross anatomic abnormalities were used in this work. All were donated to the anatomy laboratory. Prior to death, all the donors had voluntarily expressed their will to donate their bodies for anatomic education and study in accordance with current law. The local ethical committee for clinical research of our institution approved the study protocol. During preparation and dissection, we excluded 2 knees from the study after observing severe osteoarthritis (Ahlbäck grade > II) and/or significant changes in the lateral meniscus (visual meniscal tears). Finally, 10 knees were included (5 right and 5 left knees). Half of the knees corresponded to male donors and the other half, to female donors. The average age of the donors was 64.7 years (range, 50-84 years).

The protocol for specimen preparation was as follows: The day before dissection (24 hours), one of the knees was removed from the freezer (set at −20°C) and left at room temperature while wrapped in gauze soaked with saline solution. All dissection work was carried out throughout the same day, which avoided the need for refreezing or preservation with other chemical substances that could alter the structural properties of the tissues. The dissections were all performed by 2 knee surgeons (A.M.-P., G.R.) under the supervision of an anatomy professor (I.S.-N.) from the local university with 21 years of experience in the field. The professor created the dissection protocol followed for all the knees. To avoid confusion and changes in criteria during the study, the same team members were always present for all the dissections.

Dissection Protocol

The preparation of the cadaveric knees always followed the same protocol: First, the femoral and tibial diaphysis was cut 10 cm from the joint line. All the skin was carefully removed until the fascia lata was visualized on the lateral side. Subsequently, it was dissected, identified, and marked at its distal insertion in the Gerdy tubercle. Next, the biceps femoris tendon, the sciatic nerve, and the common peroneal nerve were all identified. The main lateral structures—the fibular collateral ligament (FCL), popliteal tendon (PT), and PFL—were carefully dissected until they were correctly visualized. A lateral parapatellar arthrotomy was performed. Then, the anterior and posterior cruciate ligaments were removed. Subsequently, the FCL and PT were marked and sectioned at the femoral level to disassemble the femur to expose the entire lateral compartment. In addition, the patellar bone was removed, and the patellar tendon was sectioned distally. To further facilitate the dissection, a sagittal osteotomy at the intercondylar level was performed while ensuring that the meniscal roots and other structures of interest were left undamaged. After the dissection, the main lateral

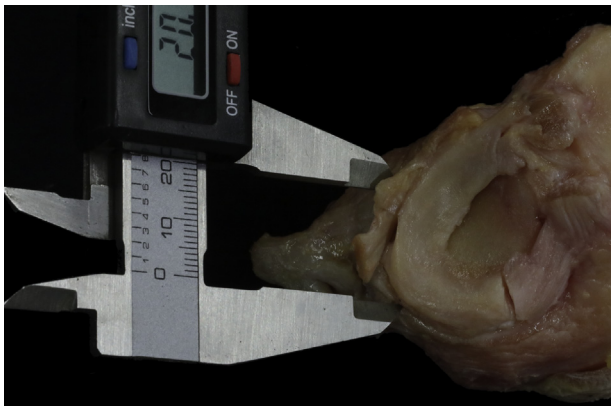

Fig 1. Anatomic dissection of a right knee. An axial view shows an example of an anteroposterior measurement using an electronic caliper.

structures—the FCL, PT, PFL, PML, and LMTL—were again correctly identified and marked.

Measurements

To prevent mistakes in measuring the landmarks established by the team, all the measurements were always determined independently by the 2 knee surgeons who participated in the dissections while under the supervision of the anatomy professor. They were performed using an electronic caliper (Digimatic Caliper; Mitutoyo, Kawasaki, Japan) with a degree of accuracy to within 0.01 mm (Fig 1). To prevent movement of the cadaveric knee during the measurements, it was fixed on a working table, and the lateral meniscus was pierced with a K-wire and fixed to the tibial plateau without damaging the peripheral attachments. All measurements were taken 3 times, and the average was recorded and used for the study. In the case of having to determine measurements with curvature, they were calculated as the sum of 3-dimensional measurements on the peripheral path of the measured structure.

Landmarks

To better define the attachments of the lateral meniscal body and its posterolateral area, all the measurements (i.e., thickness, amplitude, location, and size) of the involved structures (PFL, PML, and LMTL), as well as their relations in the lateral compartment, were in agreement with those determined by the anatomy professor. The midpoint of the FCL was taken as the anatomic reference to better differentiate between the anterior (ventral) structures (LMTL) and posterior (dorsal) structures (PFL and PML) of the proposed lateral complex (MTPFC). The measurements included (1) the mediolateral thickness of the LMTL, (2) the mediolateral thickness of the PFL-PML ligaments, (3) the anteroposterior distance of the LMTL, (4) the anteroposterior distance of the PFL-PML ligaments, (5) the anteroposterior distance of the entire complex (MTPFC), (6) the distance from the midpoint of the MTPFC to the midpoint of the posterior horn of the lateral meniscal root, (7) the distance from the midpoint of the MTPFC to the anterior horn of the lateral meniscal root, and (8) the distance from the tibial attachment of the LMTL to the articular surface of the lateral tibial plateau.

Histopathologic Study

Once all the necessary measurements were determined, samples from the 10 knees were obtained to perform a histologic study. The meniscal roots were detached, and a block that included the entire lateral meniscus attached to the MTPFC was collected. Tissue samples were fixed in 10% buffered formalin at room temperature for more than 24 hours and decalcified in a solution containing aluminum chloride, hydrochloric acid, and formic acid, based on the method of Plank and Rychlo.[23] The block was embedded in paraffin and sectioned at 7 μm. Two coronal sections were cut for each block. One included the meniscal body and the LMTL (anterior to the FCL); the other included the meniscal body and the PFL and PML (posterior to the FCL). Some sections were stained with Masson trichrome, and others, with hematoxylin-eosin.

Statistical Analysis

Categorical variables are expressed as means and standard deviations. In all cases, 95% confidence intervals (CIs) were also calculated. Interobserver agreement was analyzed using the intraclass correlation coefficient in the case of quantitative variables.[24] A score above 0.80 was defined as excellent agreement. All ICC

Table 1. Average Anatomic Measurements in 10 Cadaveric Knees Dissected

Variable	Mean (N = 10)	SD	95% CI
LMTL thickness, mm	0.62	0.18	0.49-0.75
PFL-PML thickness, mm	1.05	0.27	0.85-1.24
Anteroposterior distance of LMTL, mm	15.80	4.80	12.40-19.30
Anteroposterior distance of PFL-PML, mm	10.40	1.70	9.21-11.63
Anteroposterior distance of MTPFC, mm	28.20	4.95	24.70-31.70
Distance from MTPFC to PHLM, mm	29.30	2.29	27.60-30.90
Distance from MTPFC to AHLM, mm	32.00	4.80	28.60-35.50
Distance from LMTL tibial insertion to articular surface, mm	5.59	1.22	4.72-6.46

AHLM, anterior horn of lateral meniscus; CI, confidence interval; LMTL, lateral meniscotibial ligament; MTPFC, menisco-tibio-popliteus-fibular complex; PFL, popliteofibular ligament; PHLM, posterior horn of lateral meniscus; PML, popliteomeniscal ligament; SD, standard deviation.

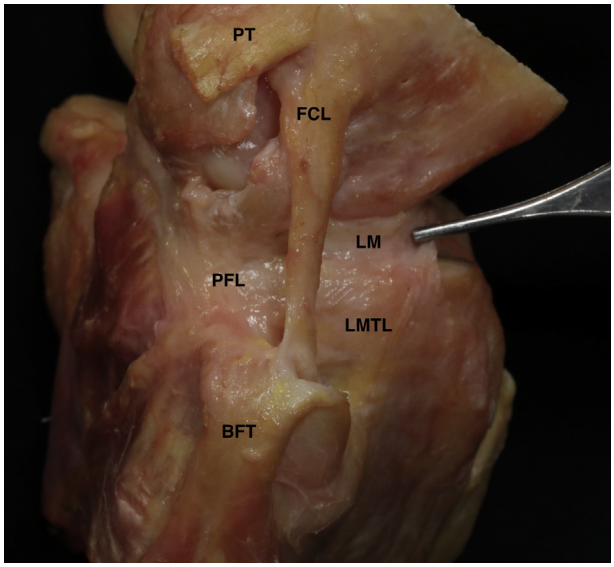

Fig 2. Anatomic dissection of a right knee. A sagittal view shows the peripheral insertions of the lateral meniscal body (LM) after the popliteal tendon (PT) and biceps femoral tendon (BFT) are sectioned, whereas the lateral meniscotibial ligament (LMTL) is tightened at the level of its most anterior meniscal insertion. The entire menisco-tibio-popliteus-fibular complex is observed, with the LMTL positioned anterior to the fibular collateral ligament (FCL) and the more posterior popliteofibular ligament (PFL).

scores were greater than 0.95 (range, 0.95-0.99). Statistical analysis was performed using the SPSS software package (version 19; SPSS, Chicago, IL).

Results

Anatomic Measurements

All the measurements obtained are shown in Table 1, expressed in millimeters ± standard deviation (95% CI). In relation to the mediolateral thickness measurement of the LMTL, the mean was 0.62 ± 0.18 mm (95% CI, 0.49-0.75 mm). The mediolateral thickness of the PFL-PML area was 1.05 ± 0.27 mm (95% CI, 0.85-1.24 mm); this area (posterior to the FCL) was thicker than the previous area (anterior to the FCL). The anteroposterior distance of the LMTL was 15.80 ± 4.80 mm (95% CI, 12.40-19.30 mm), whereas the anteroposterior distance of the PFL-PML area was 10.40 ± 1.70 mm (95% CI, 9.21-11.63 mm). In addition, the anteroposterior distance of the whole complex (MTPFC) measured 28.20 ± 4.95 mm (95% CI, 24.70-31.70 mm). The average distance from the midpoint of the MTPFC to the midpoint of the posterior horn of the lateral meniscal root was 29.30 ± 2.29 mm (95% CI, 27.60-30.90 mm), whereas the average distance from the midpoint of the MTPFC to the midpoint of the anterior horn of the lateral meniscal root was 32.00 ± 4.80 mm (95% CI, 28.60-35.50 mm). Furthermore, the average distance from the tibial insertion of the LMTL to the articular surface of the lateral tibial plateau measured 5.59 ± 1.22 mm (95% CI, 4.72-6.46 mm).

Morphologic Results

With reference to the attachments of the lateral meniscal body, the structures were found to be consistently related in all the knees dissected. Once the biceps femoris tendon and PT were sectioned and before sectioning of the FCL, a relation between the LMTL and its continuation with the PFL was observed. On a sagittal view, this combination covers the entire lateral part of the attachment of the meniscal body to the tibia (Fig 2). The origin of the LMTL is observed anterior to the FCL, whereas the end of the PFL is located posterior to the FCL. However, they are in a continuous relation, forming the MTPFC. The LMTL

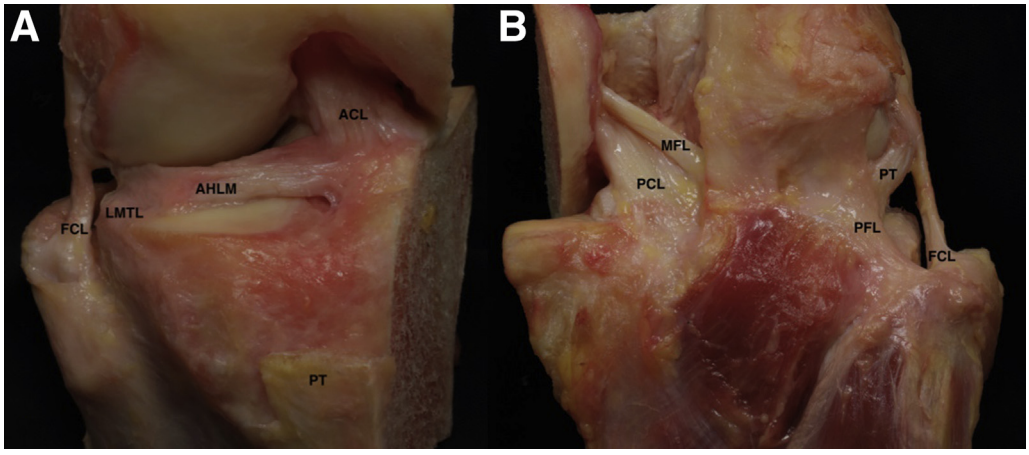

Fig 3. Anatomic dissection of a right knee. (A) Anterior view showing the more anterior attachment of the lateral meniscotibial ligament (LMTL); it is thin and loose. (ACL, anterior cruciate ligament; AHLM, anterior horn of lateral meniscus; FCL, fibular collateral ligament; PT, patellar tendon.) (B) Posterior view showing the popliteofibular ligament (PFL); it is more tense and thicker. (FCL, fibular collateral ligament, MFL, meniscofemoral ligament [ligament of Wrisberg]; PCL, posterior cruciate ligament; PT, popliteal tendon.)

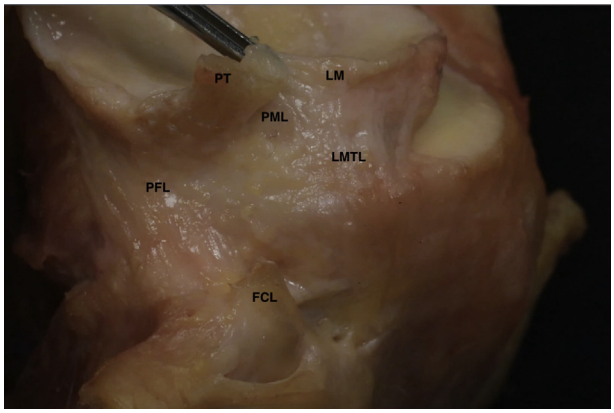

Fig 4. Anatomic dissection of a right knee: sagittal view, after the fibular collateral ligament (FCL) is sectioned, the femur is dismantled, and the lateral meniscus (LM) is tensed. A complete view of the menisco-tibio-popliteus-fibular complex is obtained, with the lateral meniscotibial ligament (LMTL) anterior to the FCL, the popliteofibular ligament (PFL) posterior, and the anterosuperior popliteomeniscal ligament (PML) more proximal. (PT, popliteal tendon.)

can be easily observed on an anterior view, being a lax thin structure that connects the meniscal body to the tibial plateau as described in the measurement results (Fig 3A). On the other hand, the PFL can be observed to be a thicker and tenser structure in comparison to the LMTL on a posterior view (Fig 3B).

To further explore the lateral compartment, the FCL and the anterior and posterior cruciate ligaments were sectioned and the femur was disassembled. The continuity of ligament fibers from the most anterior part of the LMTL to the most posterior part of the PFL, as seen on a lateral view, was confirmed in all the knees. The former (LMTL) had a more vertical orientation, whereas the latter (PFL) had a more diagonal orientation. This fiber change seemed to happen at the level of the FCL, one of the anatomic references. Regardless of the orientation, continuity between them and the connection of these 2 structures was clearly observed in all the knees. They make up a lateral complex (MTPFC) together with the PML that is located more proximal (Fig 4). Again, the LMTL in the most anterior (ventral) region of the MTPFC is easily identifiable (Fig 5), similarly to the PFL in its more posterior (dorsal) region (Fig 6). On the other hand, the PML was clearly identified and found in all the knees. It joins the PT to the lateral meniscal body with an anterosuperior fascicle and a posterosuperior fascicle. The PML also links the LMTL and PFL (Fig 7).

Finally, both meniscal roots were sectioned to access an internal view of the structures. Once again, a constant and reproducible anatomic disposition was observed in all the knees. This made it possible to distinguish the MTPFC structures from a perspective different from the conventional lateral view, again verifying the relation between all the structures involved (Fig 8). Likewise, the entire lateral meniscus was flipped, thereby obtaining a reliable internal view of the tissues that connect the body of the lateral meniscus to the peripheral structures (Fig 9).

Histopathologic Results

Samples were collected for a pathologic study of all the knees, as described in the "Methods" section. Because the impression during the dissections was that there might be structural differences between the 2 tissues, 2 coronal sections of the MTPFC, anterior and posterior to the FCL fibers, were performed. In all cases, the same histologic pattern was observed. There was loose, thin tissue in the LMTL area and more dense and structured tissue in the PFL and PML area (Fig 10).

Discussion

The most important finding in this study was that the same anatomic pattern of the lateral meniscal attachment was identified in all specimens around the lateral meniscal body. This lateral complex pattern was constant in all the knees dissected. It consists of 3 interconnected ligaments (LMTL, PFL, and PML) with the proposed denomination of "MTPFC." All the structures composing the MTPFC displayed the same quantitative pattern in all the studied knees regardless of the morphologic differences (i.e., donor height and weight). Throughout the investigation, the fibers located anterior to the FCL (corresponding to the LMTL) were looser and thinner whereas those located beyond the FCL (corresponding to the PFL and PML) were denser and thicker and had much more cellularity. All these findings support our hypotheses.

Because of the confusing terminology and the various ways in which it has been described, there is little

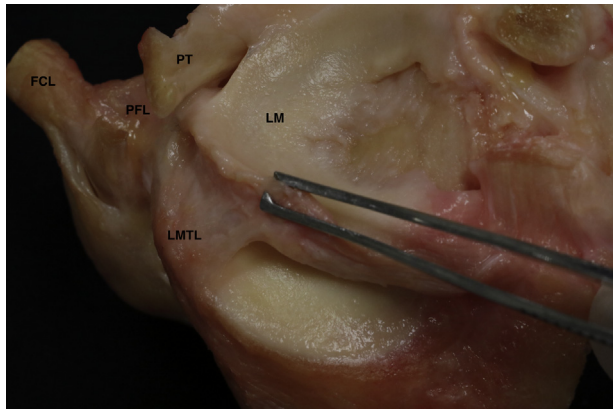

Fig 5. Anatomic dissection of a right knee: anterior coronal view of the lateral meniscotibial ligament (LMTL), linking the lateral meniscal (LM) body to the tibial plateau. (FCL, fibular collateral ligament; PFL, popliteofibular ligament; PT, popliteal tendon.)

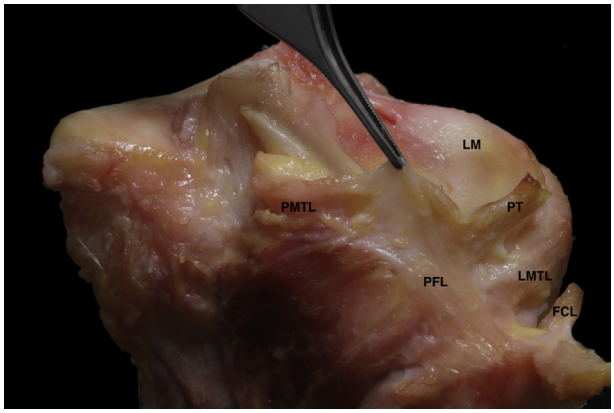

Fig 6. Anatomic dissection of a right knee. The popliteofibular ligament (PFL) is observed from a posterior coronal view while the lateral meniscus (LM) is tensed. (FCL, fibular collateral ligament; LMTL, lateral meniscotibial ligament; PMTL, posterior meniscotibial ligament; PT, popliteal tendon.)

agreement in the literature around the anatomy of this area and its relation with the body of the lateral meniscus. It is true that a reference was made to a capsular reinforcement in the lateral region of the knee attached from the lateral meniscus to the tibia[1] in classic treatises on anatomy. However, it was not until 1964 that it appeared specifically in the literature with the name of "MFL,"[13] even though it had previously been described in animals.[25] Later, other authors also referenced this structure, speculating that it might offer protection from damage to the lateral meniscus during the last stages of knee extension and reinforcement of the posterolateral part of the coronary ligament.[14] Still other authors have affirmed that there is a potential relation between the MFL and the proximal tibiofibular joint. They have postulated that the MFL may be responsible for the backward and outward displacement of the lateral meniscus because the fibula rotates laterally during dorsiflexion of the ankle joint.[15]

The nomenclature for this area is erroneous and gives rise to confusion, as shown in our investigation. The structure to which these authors refer clearly originates in the body of the lateral meniscus and inserts about 5.59 ± 1.22 mm (95% CI, 4.72-6.46 mm) under the tibial articular surface (Fig 3A). Here, it is differentiated from more posterior structures such as the PFL with which it has continuity (Fig 4), which is also part of the described lateral complex. Therefore, we believe that the correct nomenclature for this structure should be "lateral meniscotibial ligament" (LMTL), as it is consensually known on the medial side of the knee.[26,27] In fact, in the literature, very few authors have referred to the "meniscotibial ligament." When they have, it was described as capsular fibers with a proximal origin in the lateral border of the menisci and a distal insertion in the lateral border of the tibial plateau. To confuse the issue even more, it has also

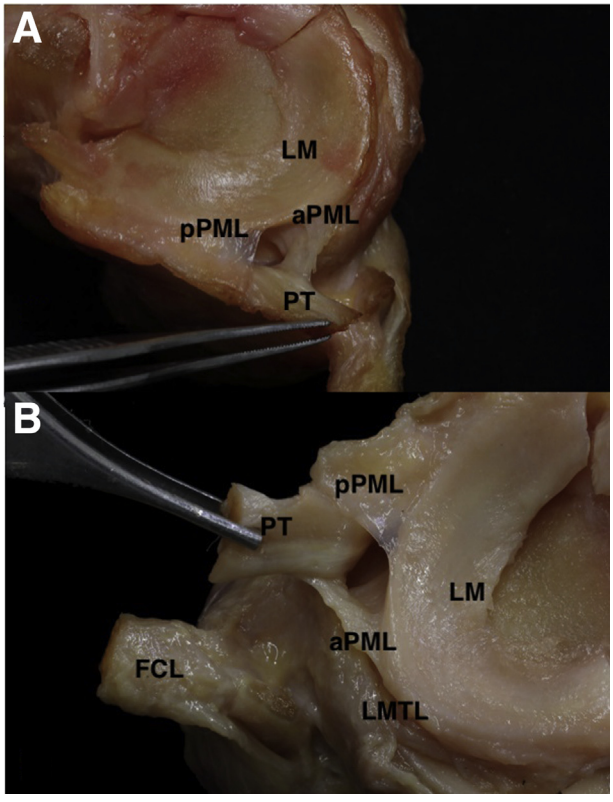

Fig 7. Anatomic dissection of a right knee. (A) Posterior axial view of the lateral meniscus (LM). The 2 fascicles of the popliteomeniscal ligament are easily identified after a careful dissection procedure: posterosuperior popliteomeniscal ligament (pPML) and anterosuperior popliteomeniscal ligament (aPML). (B) Anterior axial view with the aPML and pPML identified. (FCL, fibular collateral ligament; LMTL, lateral meniscotibial ligament; PT, popliteal tendon.)

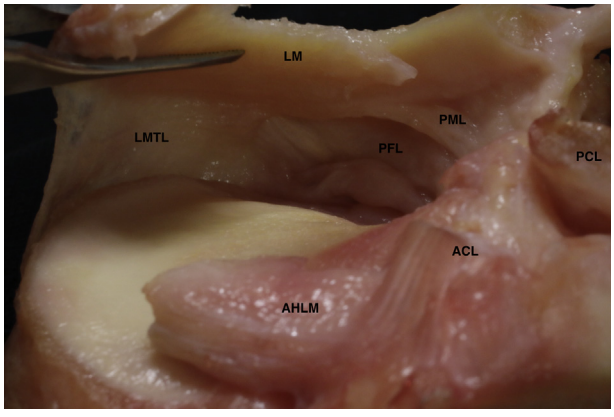

Fig 8. Anatomic dissection of a right knee: internal view of the lateral meniscal body with both roots detached and the lateral meniscus (LM) pulled proximally. The lateral meniscotibial ligament (LMTL) is located anteriorly; subsequently, the popliteomeniscal ligament (PML) and popliteofibular ligament (PFL) are observed posteriorly. (ACL, anterior cruciate ligament; AHLM, anterior horn of lateral meniscus; PCL, posterior cruciate ligament.)

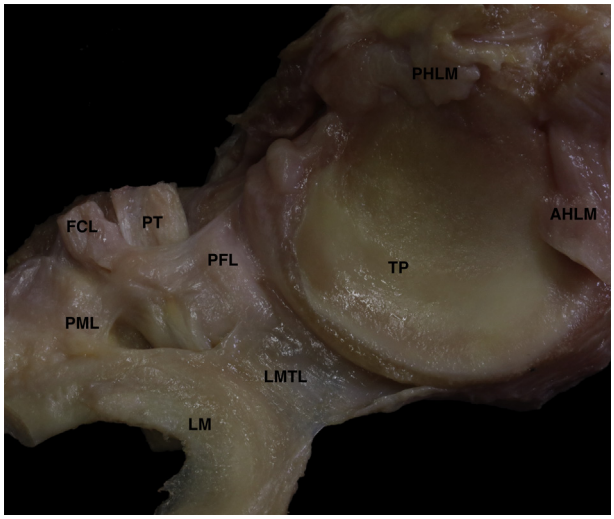

Fig 9. Anatomic dissection of a right knee. The meniscal roots are sectioned, and the lateral meniscus (LM) is flipped and tensioned to show the entire menisco-tibio-popliteus-fibular complex from an inner side. (AHLM, anterior horn of lateral meniscus; FCL, fibular collateral ligament; LMTL, lateral meniscotibial ligament; PFL, popliteofibular ligament; PHLM, posterior horn of lateral meniscus; PML, popliteomeniscal ligament; PT, popliteal tendon; TP, tibial plateau.)

been referred to as the "coronary ligament." Unlike in our study, those few authors found this structure in only 23% of the knees evaluated.[16,28] Furthermore, other studies have made reference to this lateral structure in which it was simply described as a portion of the mid-third capsular ligament. It is considered clinically important for being an area of either soft-tissue or bony Segond avulsion during posterolateral corner injuries.[3,17] A recent study has qualitatively and quantitatively described the anatomy of the posterior horn of the lateral meniscus, the popliteomeniscal fascicles, and the posterolateral capsule.[29] However, the authors described the meniscotibial ligament as a posterior structure. In our study, this corresponds to the coronary ligament or posterior meniscotibial ligament. Whereas they described a large part of the lateral structures adjacent to the lateral meniscal body as the "capsule," we believe they overlooked important structures such as the LMTL.

The PFL runs from the tendon of the popliteal muscle (proximal to the myotendinous junction) to the fibular head (posterior to the attachment of the FCL).[30] However, we also have seen portions of this structure linking the lateral meniscal body, the LMTL, and the tibial plateau (Figs 4 and 6). The literature describes 2 types

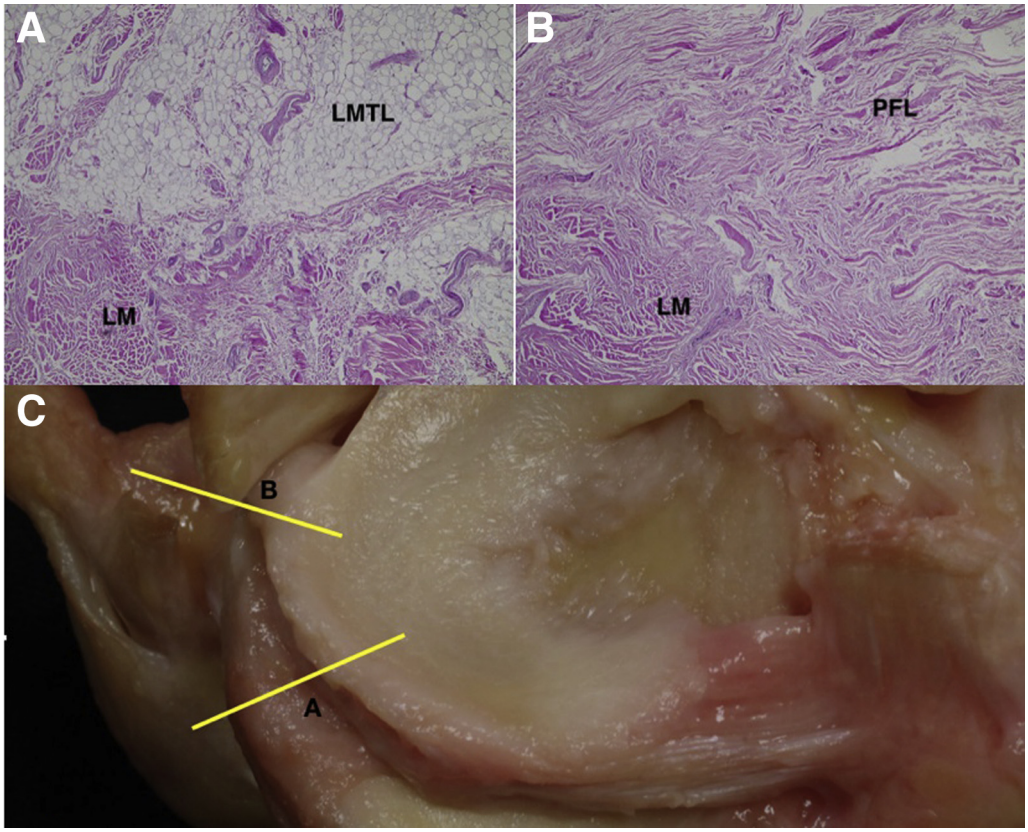

Fig 10. Histologic sections of the transition between the lateral meniscal body (LM) and the lateral meniscotibial ligament (LMTL) (A) and the transition between the lateral meniscal body and the popliteofibular ligament (PFL) (B) (hematoxylin-eosin stain, original magnification ×100) and anatomic dissection (C) of a right knee.

of PFL: type I has 1 layer, whereas type II has 2 layers. In a cadaveric study, type I PFL was identified in 69.2% of specimens and type II, in 30.8%.[31] In our study, we observed that the mean thickness of the structures corresponding to the LMTL was 0.62 ± 0.18 mm (95% CI, 0.49-0.75 mm) and that of the PFL was 1.05 ± 0.27 mm (95% CI, 0.85-1.24 mm), whereas Bozkurt et al.[15] found the mean thickness of the MFL to be 3.84 mm, ranging from 2.6 to 6.1 mm, including the capsule to which it adheres. Such a thickness was greater than the thickness detected by us and by Zivanovic.[13] We believe that their measurements incorporated part of the lateral capsule given that we have observed that they are consistently finer structures in all our dissections. In addition, it was possible for us to clearly differentiate them from more superficial tissues such as those of the lateral capsule (Figs 5, 8, and 9). For this reason and on the basis of the observed histology, we hypothesized that the entire MTPFC would play a role in preventing lateral meniscal extrusion. Nonetheless, the PFL and PML would contribute more to rotational stabilization and the LMTL to axial stabilization because of the location, distribution and orientation of their fibers.

The term "coronary ligament," which is located in the posterior area near the meniscal root, is also used to refer to the posterior meniscotibial ligament.[3,17] It has a structure and location that are totally different from those of the LMTL, as shown in our study. The coronary ligament on the medial side has been extensively studied[27,32] and related to lesions of the posteromedial region. In addition, the posterior structures of the lateral compartment have been revised and related to lesions in this area.[33-35] It is known that the lateral meniscus has greater anteroposterior mobility than the medial meniscus, and it is here where the coronary ligament or the posterior meniscotibial ligament can have a restrictive role.[36] The role that the meniscofemoral ligament[37] and PML[20-22] have relative to the stability of the lateral meniscus is also widely known. In addition, the lateral meniscus plays an important role in axial load restrictions.[38] Therefore, we believe that the MTPFC may have a restrictive role in preventing axial extrusion of the lateral meniscus. In this sense, with application to clinical practice, some authors have tried to reproduce surgical techniques that can mimic the role that the LMTL, PFL, or PML may play in preventing extrusion in the native meniscus.[39] Their aim was to limit lateral extrusion after lateral meniscal allograft transplantation. Biomechanical studies focused on this aspect would be necessary to further corroborate our hypothesis.

Limitations

Different limitations to this investigation need to be addressed. Because knees of donors younger than 50 years were not used, we cannot ensure that the studied structures did not undergo a process of degeneration throughout life that could have altered the measurements made. These measurements might differ from those in the population younger than 50 years. However, some mild degree of meniscal degeneration or pre-existing extrusion in the dissected knees that could have altered the anatomy and its measurements could have gone unnoticed. Likewise, even though all the results were constant and homogeneous in our study, we do not know whether there are anatomic variants in terms of race because all the knees were from white donors. Finally, in the case of having to determine measurements with curvature, it may have been more accurate to measure directly on the bone.

Conclusions

A consistent anatomic pattern has been identified between the lateral meniscal body and the LMTL, PFL, and PML, forming an interconnected complex that would seem appropriate to denominate the MTPFC. A precise study of this region and appropriate nomenclature for it could contribute to a better understanding of the mechanism of lateral meniscal injuries at this level, as well as the development of surgical techniques to treat these lesions and prevent extrusion.

Acknowledgment

The authors thank Sergi Mojal for assisting in the statistical analysis as well as Eric Goode for his help in correcting the manuscript and Francesc Tresserra-Casas, M.D., Ph.D., for contributing to the histopathologic study.

References

1. Testut L. *Traite d'anatomie humaine*. Paris: Doin, 1904;964-965.
2. Testut L, Jacob O. *Tratado de anatomía topográfica*. Ed 8, Vol 2. Barcelona: Salvat, 1972.
3. Moorman CT III, LaPrade RF. Anatomy and biomechanics of the posterolateral corner of the knee. *J Knee Surg* 2005;18:137-145.
4. Thaunat M, Pioger C, Chatellard R, et al. The arcuate ligament revisited: Role of the posterolateral structures in providing static stability in the knee joint. *Knee Surg Sports Traumatol Arthrosc* 2014;22:2121-2127.
5. Rath E, Richmond JC. The menisci: Basic science and advances in treatment. *Br J Sports Med* 2000;34:252-257.
6. Servien E, Acquitter Y, Hulet C, Seil R, French Arthroscopy Society. Lateral meniscus lesions on stable knee: A prospective multicenter study. *Orthop Traumatol Surg Res* 2009;95:S60-S64 (suppl 1).
7. Van Steyn MO, Mariscalco MW, Pedroza AD, Smerek J, Kaeding CC, Flanigan DC. The hypermobile lateral meniscus: A retrospective review of presentation, imaging, treatment, and results. *Knee Surg Sports Traumatol Arthrosc* 2016;24:1555-1559.

8. Arnoczky SP, Warren RF. Microvasculature of the human meniscus. *Am J Sports Med* 1982;10:90-95.
9. Raheem O, Philpott J, Ryan W, O'Brien M. Anatomical variations in the anatomy of the posterolateral corner of the knee. *Knee Surg Sports Traumatol Arthrosc* 2007;15:895-900.
10. Davies H, Unwin A, Aichroth P. The posterolateral corner of the knee: Anatomy, biomechanics and management of injuries. *Injury* 2004;35:68-75.
11. Cooper JM, McAndrews PT, LaPrade RF. Posterolateral corner injuries of the knee: Anatomy, diagnosis, and treatment. *Sports Med Arthrosc Rev* 2006;14:213-220.
12. LaPrade RF, Morgan PM, Wentorf FA, Johansen S, Engebretsen L. The anatomy of the posterior aspect of the knee: An anatomic study. *J Bone Joint Surg Am* 2007;89:758-764.
13. Zivanovic S. The menisco-fibular ligament of the knee joint. *Acta Vet* 1973;23:89-94.
14. Natsis K, Paraskevas G, Anastasopoulos N, Papamitsou T, Sioga A. Meniscofibular ligament: Morphology and functional significance of a relatively unknown anatomical structure. *Anat Res Int* 2012;2012:214784.
15. Bozkurt M, Elhan A, Tekdemir I, Tönük E. An anatomical study of the meniscofibular ligament. *Knee Surg Sports Traumatol Arthrosc* 2004;12:429-433.
16. Bezerra FS, Alves JN, Silva MAS, et al. Quantitative and descriptive analysis of the meniscotibial ligament in human corpses. *Braz J Morphol Sci* 2007;24:211-213.
17. Terry GC, Laprade RF. The biceps femoris muscle complex at the Knee. Its anatomy and injure patterns associated with acute anterolateral-anteromedial rotatory instability. *Am J Sports Med* 1996;24:2-8.
18. Gupte CM, Bull AM, Murray R, et al. Comparative anatomy of the meniscofemoral ligament in humans and some domestic mammals. *Anat Histol Embryol* 2007;36:47-52.
19. Terry GC, LaPrade RF. The posterolateral aspect of the knee. Anatomy and surgical approach. *Am J Sports Med* 1996;24:732-739.
20. Staubli HU, Birrer S. The popliteus tendon and its fascicles at the popliteal hiatus: Gross anatomy and functional arthroscopic evaluation with and without anterior cruciate ligament deficiency. *Arthroscopy* 1990;6:209-220.
21. Simonian PT, Sussmann PS, van Trommel M, Wickiewicz TL, Warren RF. Popliteomeniscal fasciculi and lateral meniscal stability. *Am J Sports Med* 1997;25:849-853.
22. Simonian PT, Sussmann PS, Wickiewicz TL, et al. Popliteomeniscal fasciculi and the unstable lateral meniscus: Clinical correlation and magnetic resonance diagnosis. *Arthroscopy* 1997;13:590-596.
23. Plank J, Rychlo A. A method for quick decalcification. *Zentralbl Allg Pathol* 1952;89:252-254 [in German].
24. Hale CA, Fleiss JL. Interval estimation under two study designs for kappa with binary classification. *Biometrics* 1993;49:523-534.
25. Haines RW. The tetrapod knee joint. *J Anat* 1942;76:270-301.
26. LaPrade RF, Engebretsen AH, Ly TV, et al. The anatomy of the medial part of the knee. *J Bone Joint Surg Am* 2007;89:2000-2010.
27. Peltier A, Lording T, Maubisson L, Ballis R, Neyret P, Lustig S. The role of the meniscotibial ligament in posteromedial rotational knee stability. *Knee Surg Sports Traumatol Arthrosc* 2015;23:2967-2973.
28. Wang YJ, Yu JK, Luo H, et al. An anatomical and histological study of human meniscal horn bony insertions and peri-meniscal attachments as a basis for meniscal transplantation. *Chin Med J (Engl)* 2009;122:536-540.
29. Aman ZS, DePhillipo NN, Storaci HW, et al. Quantitative and qualitative assessment of posterolateral meniscal anatomy: Defining the popliteal hiatus, popliteomeniscal fascicles, and the lateral meniscotibial ligament. *Am J Sports Med* 2019;47:1797-1803.
30. Bolog N, Hodler J. MR imaging of the posterolateral corner of the knee. *Skeletal Radiol* 2007;36:715-728.
31. Ishigooka H, Sugihara T, Shimizu K, Aoki H, Hirata K. Anatomical study of the popliteofibular ligament and surrounding structures. *J Orthop Sci* 2004;9:51-58.
32. DePhillipo NN, Moatshe G, Brady A, et al. Effect of meniscocapsular and meniscotibial lesions in ACL-deficient and ACL-reconstructed knees: A biomechanical study. *Am J Sports Med* 2018;46:2422-2431.
33. Diamantopoulos A, Tokis A, Tzurbakis M, Patsopoulos I, Georgoulis A. The posterolateral corner of the knee: Evaluation under microsurgical dissection. *Arthroscopy* 2005;21:826-833.
34. Frank JM, Moatshe G, Brady AW, et al. Lateral meniscus posterior root and meniscofemoral ligaments as stabilizing structures in the ACL-deficient knee: A biomechanical study. *Orthop J Sports Med* 2017;5:2325967117695756.
35. Geeslin AG, Civitarese D, Turnbull TL, Dornan GJ, Fuso FA, LaPrade RF. Influence of lateral meniscal posterior root avulsions and the meniscofemoral ligaments on tibiofemoral contact mechanics. *Knee Surg Sports Traumatol Arthrosc* 2016;24:1469-1477.
36. Thompson WO, Thaete FL, Fu FH, Dye SF. Tibial meniscal dynamics using three-dimensional reconstruction of magnetic resonance images. *Am J Sports Med* 1991;19:210-216.
37. Poynton A, Moran CJ, Moran R, O'Brien M. The meniscofemoral ligaments influence lateral meniscal motion at the human knee joint. *Arthroscopy* 2011;27:365-371.e2.
38. Musahl V, Citak M, O'Loughlin PF, Choi D, Bedi A, Pearle AD. The effect of medial versus lateral meniscectomy on the stability of the anterior cruciate ligament-deficient knee. *Am J Sports Med* 2010;38:1591-1597.
39. Masferrer-Pino A, Monllau JC, Ibáñez M, Erquicia JI, Pelfort X, Gelber PE. Capsulodesis versus bone trough technique in lateral meniscal allograft transplantation: Graft extrusion and functional results. *Arthroscopy* 2018;34:1879-1888.