

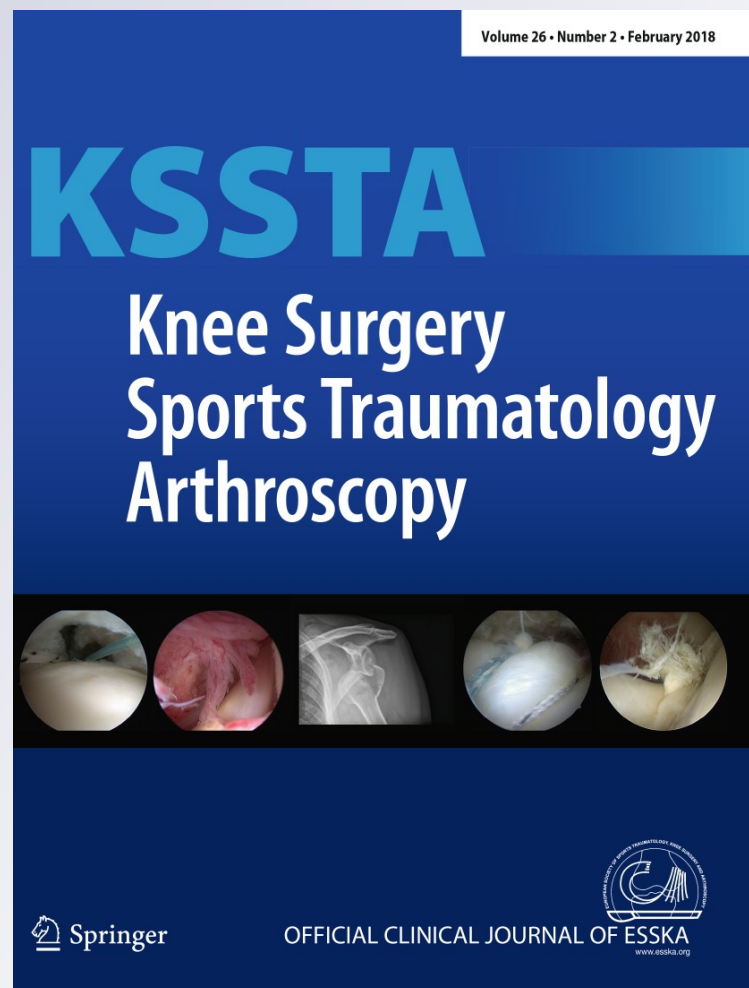
*Contamination occurs during ACL graft harvesting and manipulation, but it can be easily eradicated*

**Daniel Pérez-Prieto, María E. Portillo,  
Raúl Torres-Claramunt, Xavier Pelfort,  
Pedro Hinarejos & Joan C. Monllau**

**Knee Surgery, Sports Traumatology,  
Arthroscopy**

ISSN 0942-2056  
Volume 26  
Number 2

Knee Surg Sports Traumatol Arthrosc  
(2018) 26:558-562  
DOI 10.1007/s00167-017-4735-z



 Springer

**Your article is protected by copyright and all rights are held exclusively by European Society of Sports Traumatology, Knee Surgery, Arthroscopy (ESSKA). This e-offprint is for personal use only and shall not be self-archived in electronic repositories. If you wish to self-archive your article, please use the accepted manuscript version for posting on your own website. You may further deposit the accepted manuscript version in any repository, provided it is only made publicly available 12 months after official publication or later and provided acknowledgement is given to the original source of publication and a link is inserted to the published article on Springer's website. The link must be accompanied by the following text: "The final publication is available at [link.springer.com](http://link.springer.com)".**

## Contamination occurs during ACL graft harvesting and manipulation, but it can be easily eradicated

Daniel Pérez-Prieto<sup>1</sup> · María E. Portillo<sup>2</sup> · Raúl Torres-Claramunt<sup>1</sup> · Xavier Pelfort<sup>3</sup> · Pedro Hinarejos<sup>1</sup> · Joan C. Monllau<sup>1</sup>

Received: 11 April 2017 / Accepted: 26 September 2017 / Published online: 7 October 2017  
© European Society of Sports Traumatology, Knee Surgery, Arthroscopy (ESSKA) 2017

### Abstract

**Purpose** Why anterior cruciate ligament (ACL) autograft soaking in a 5 mg/ml vancomycin solution decreases the rate of infection has not been well-explained. One hypothesis is that grafts can be contaminated during harvesting and vancomycin eradicates the bacteria. The purpose of the present study is to assess how the vancomycin solution acts against ACL graft contamination during graft harvesting and preparation.

**Methods** The study was carried out in three university hospitals over a period of 6 months. After sample size calculation, 50 patients were included in the study. Three samples were taken from each ACL graft. Sample 1 was obtained immediately after graft harvesting. After graft manipulation and preparation, the remaining tissue was divided into two parts. The raw sample was denominated sample 2 and sample 3 consisted of the rest of the remaining tissue that had been soaked in the vancomycin solution. All the cultures were incubated at 37 °C with 5% CO<sub>2</sub> in agar plates for 7 days (aerobically) or 14 days (anaerobically) and inspected daily for microbial growth. Any bacterial growth and the number of colony forming units were reported.

**Results** In seven cases (14%), either sample 1 or sample 2 was positive. In five of the cases (10%), only the sample

after graft preparation was positive (sample 2). In two cases (4%), sample 1 and sample 2 were positive for the same bacteria. Isolated microorganisms corresponded to coagulase-negative staphylococci (CNS) and *Propionibacterium acnes*. No bacterial growth was observed in sample 3 ( $p < 0.001$ ). Thus, none of those seven positive cases (0%) were positive after vancomycin soaking ( $p < 0.001$ ).

**Conclusion** In the series, ACL graft harvesting and manipulation leads to bacterial contamination in 14% of the cases. This contamination is fully eradicated after soaking in the vancomycin solution in this series.

**Level of evidence** Level II.

**Keywords** ACL infection · Biofilm · Vancomycin soaking · Infection prevention · ACL contamination

### Introduction

Septic knee arthritis after anterior cruciate ligament reconstruction (ACLR) has an estimated rate of approximately 1.5%, which is a slightly lower reported incidence than other orthopedic related infection [24, 28]. It has been described as the most feared and devastating complication [26]. However, a comprehensive treatment approach has shown cure rates of around 100% and better functional outcomes than other complications like ACLR-related fractures or arthrofibrosis [3, 11, 16]. To achieve it, arthroscopic debridement with graft retention along with antibiofilm antibiotics has shown optimal results in most series [13, 20, 23].

Most recently, a technique has been described to prevent ACLR infection. This measure consists of soaking the graft in a vancomycin solution. By doing so, a reduction in the infection rate to 0% in several series has been demonstrated [19, 21, 29]. With this procedure, the graft acts as

✉ Daniel Pérez-Prieto  
dperezprieto@parcdesalutmar.cat

<sup>1</sup> Department of Orthopaedic Surgery and Traumatology, Hospital del Mar, Universitat Autònoma de Barcelona (UAB), Passeig Marítim, 25, Barcelona, Spain

<sup>2</sup> Microbiology Department, Hospital de Navarra, Pamplona, Spain

<sup>3</sup> Orthopedic Surgery, Consorci Sanitari de l'Anoia, Igualada, Spain

an antibiotic reservoir eluting vancomycin over most of the microorganisms' minimal inhibitory concentration (MIC) for 24h [9]. This is the critical period when planktonic bacteria can attach itself to the implant or the avascular graft as both are recognized as foreign bodies [30].

Another supposed mechanism is that the vancomycin solution acts to kill the supposed bacteria which may contaminate the graft during harvesting [27]. Surprisingly, no previous study has focused on this theory.

The purpose of the present study is to assess how the vancomycin solution acts against ACL graft contamination during graft harvesting and preparation. The hypothesis is that the vancomycin solution reduces contamination rates during ACL graft harvesting and preparation.

## Materials and methods

A prospective controlled study was performed. The study was approved by the Ethics Committee (DEXEUS-CONT-BACT 6/16). All patients operated on for ACLR in three university hospitals were included. Those patients that needed an extraarticular procedure or those who received an allograft were excluded from the study. Patients with the previous knee surgeries or previous knee punctures were also excluded. The patients were operated on between June 2016 and December 2016.

During the study period, a total of 87 ACLR were initially included in the study. Thirty-seven out of these eighty-seven patients were excluded, because they did not meet the inclusion criteria. Thus, 50 patients were included for the present study and there were no further losses.

## Surgical protocol

A quadrupled hamstrings' autograft or bone-patellar tendon-bone (BPTB) autograft was chosen depending on the patients' characteristics and surgeons' preferences. All operations were performed on an outpatient basis. Therefore, no drains were used after surgery. The prophylactic antibiotic protocol consisted of a single dose of 2 g of preoperative IV cefazolin or a single dose of 1 g of preoperative IV vancomycin if a type 1 penicillin allergy had been reported. As a part of the usual protocol, the ACL graft is always soaked in a vancomycin solution of 5 mg/ml. The solution was prepared by mixing 100 ml of sterile saline with 500 mg of vancomycin powder in a tray. After obtaining and preparing the graft, it was immersed in the tray, and then, it was wrapped in gauze that had been saturated with the vancomycin solution beforehand. The graft was left there for 10–15 min immediately prior to its use in the ACLR.

## Source of samples

Three samples were taken from each ACL graft at three distinct points in time. The first sample (sample 1) was obtained immediately after graft harvesting. After graft preparation, the remaining tissue was divided into two parts: one of them was tagged as the second sample (sample 2) and the remaining tissue was soaked in the vancomycin solution with the graft that was to be implanted (sample 3).

A minimum sample size of 1–3 mm<sup>3</sup> was requested in all cases to allow further analysis.

## Microbiological protocol

Each tissue was sent in separate sterile containers to the microbiological department. All cultures were incubated at 37 °C with 5% CO<sub>2</sub> in agar plates for 7 days (aerobically) or 14 days (anaerobically) and inspected daily for microbial growth. Any bacterial growth and the number of colony forming units were reported. Strain identification and a susceptibility test were performed using standard microbiological techniques. After study completion, each positive culture was re-evaluated by an experienced microbiologist specialized in orthopedic-related infections.

## Statistical analysis

Continuous variables were presented as means (with standard deviation, SD) and ranges as percentages. Categorical data were compared between groups with the Chi-square test. A *p* value under 0.05 was considered statistically significant.

The Chi-square difference test was used to determine the sample size. It was assumed that there would be 17% contamination in group sample 1 and group sample 2 (as previously reported by Badran [2]) and 0% contamination in group sample 3. Accepting an alpha risk of 0.05 and a beta risk of 0.2 in a two-sided test, 50 subjects were necessary to recognize a difference consisting in an initial proportion of 0.17 and a final proportion of 0 as statistically significant. A drop-out rate of 5% was anticipated.

The statistical analysis was done using the SPSS Statistics 18.0 software package (SPSS Inc., Chicago, IL).

## Results

There were 26 men and 24 women, and the mean age of the sample was 36.2 years (SD 11.4 years). In 29 patients, an autologous BPTP was used and 21 were treated with autologous quadrupled hamstrings. No differences in terms of

contamination were observed when hamstring and BPTB grafts were compared ( $p=0.684$ ). None of the patients developed septic arthritis in this series.

### Contamination during harvesting and manipulation

In seven cases (14%), either sample 1 or sample 2 was positive. In five cases (10%), only the sample after graft harvest and preparation was positive (sample 2). In two cases (4%), sample 1 and sample 2 were positive for the same bacteria. Isolated microorganisms corresponded to coagulase-negative staphylococci (CNS) and *Propionibacterium acnes*. More data about those five cases can be seen in Table 1.

### The effect of vancomycin soaking on contamination

No bacterial growth was observed in sample 3 ( $p<0.001$ ). Thus, none of those seven positive cases (0%) was positive after vancomycin soaking ( $p<0.001$ ).

## Discussion

The results of the present study suggest that the ACL auto-graft is contaminated with bacteria during surgery in 14% of the cases, most often during its preparation. That contamination was completely eradicated (0%) using a 5 mg/ml vancomycin solution, thereby confirming the hypothesis.

Infections after ACLR are a potentially serious complication, but they are curable if a proper treatment is performed. For this reason, there is an increased interest in their surgical management and antibiotic treatment. The etiology has been also widely studied. Staphylococci are the most important causative agents in up to 90% of cases. Approximately half of those are due to CNS [5, 26]. Other frequently reported pathogens are *P. acnes* and occasionally enterococci, enterobacteriaceae, and *Pseudomonas* spp. [20]. *Staphylococcus lugdunensis* is considered a CNS due to the lack of production of secreted coagulase. Despite this microorganism being susceptible to most antibiotics, *S. lugdunensis* is more

virulent than other coagulase-negative staphylococci and behaves like *S. aureus* in many clinical situations. Therefore, this one should be considered a virulent microorganism which can cause acute infections, including implant-associated infections [25]. It is very rarely reported as a causative agent for ACLR infections [17] as has been found in the present study where this microorganism was isolated in only one sample.

The high prevalence of CNS in acute infections is not seen in other orthopedic-related infections [30]. For this reason, some authors have related this factor to a possible contamination during harvesting and manipulation [5, 19, 20, 27]. Recently, Badran et al. have found a 17% rate of contamination during hamstring harvesting where most of the cases were due to CNS [2]. Quite the same was observed by Gavriilidis et al. They reported a 10% contamination rate [8]. Similar results have been found in the present study with a 10% rate of contamination, 60% of which were caused by CNS. Another study focused on both BPTB and hamstring grafts contamination showed similar results [10]. The only study that found a significantly higher rate of contamination is the one by Nakayama et al. in which they obtained 46% of positive samples [18]. However, this study should be carefully looked at as they used swabs for culture purposes. This technique is not recommended by experienced microbiologists [31].

Then again, it is important to understand that contamination is not equal to infection as there are factors that can kill bacteria such as preoperative antibiotic prophylaxis and the patient's own immune response. This is the reason studies on perioperative contamination during orthopedic procedures obtain higher rates than the reported clinical infection rates [1].

The relevance of ACLR infections is also shown in the studies focused on prevention. Special attention should be paid to the vancomycin soaking technique that has been recommended as a part of a protocol to reduce ACLR infection rates [14]. This simple practice that uses a solution of 5 mg/ml of vancomycin to impregnate the graft has proven to be effective in infection prevention [19,

**Table 1** Details of the seven cases with positive samples

Hospital number	Age	Sex	Graft type	Sample 1	Sample 2	Sample 3
1	34	Male	BPTB	Negative	<i>S. epidermidis</i>	Negative
1	27	Female	Hamstrings	Negative	<i>P. acnes</i>	Negative
2	18	Male	BPTB	Negative	<i>S. epidermidis</i>	Negative
2	51	Male	Hamstrings	Negative	<i>S. Lugdunensis</i>	Negative
3	26	Female	BPTB	Negative	<i>S. epidermidis/S. auricularis</i>	Negative
1	56	Male	BPTB	<i>P. acnes</i>	<i>P. acnes</i>	Negative
1	55	Female	BPTB	<i>S. caprae</i>	<i>S. caprae</i>	Negative

21]. Similar results have been found here as none of the patients in the current series developed septic arthritis after ACLR. Although the follow-up in the present study is very short, a clear majority of ACLR infections occur in the first 4–6 weeks [27].

Vancomycin is a useful bactericidal agent against staphylococci and enterococci and has been described as an alternative in the treatment of *P. acnes* implant-associated infections [22, 30]. Vancomycin has been shown to be safe for local use, and it has already been used in both local prophylaxis and treatment in orthopedics [7]. When the graft is soaked, it acts as an antibiotic reservoir that will be eluted for hours over the MIC of the aforementioned microorganisms [9]. The other path that the soaking technique could act on to achieve a reduction in infection is by killing the contamination that occurs during graft harvesting and preparation. There is no previous report of this theory, but the present study supports the mechanism of ACLR infection reduction. Indeed, no sample was positive for any microorganism after soaking in vancomycin. Furthermore, all patients' samples in which contamination occurred were negative for bacterial growth after vancomycin soaking.

The last consideration is the comparison between the two different types of grafts employed. It has been stated that hamstring grafts have a greater risk of infection than BPTB [4, 15]. One hypothesis is that the more complex hamstrings preparation procedure and the presence of more sutures, that can act as an "extra" foreign body, will lead to more contamination [6, 12, 20]. The comparison between graft types presented here should be analyzed with caution, because it was not the purpose and due to the small sample of cases. In any case, no differences were found in the present study between BPTB and hamstring grafts in terms of contamination, similar to the results obtained by Hantes et al [10].

Some limitations can be found in the present study, the most important being the practical correlation of contamination with infection. However, the bacteria that have been identified are the same as found in clinical practice. Another limitation might be the fact that three different microbiology departments analyzed the samples. However, an experienced microbiologist specialized in orthopedic-related infections reviewed the positive samples to reduce this possible bias. The small cohort of patients could be considered another limitation, but a sample size calculation was made beforehand.

More studies should be performed to evaluate other aspects of the vancomycin soaking technique such as vancomycin joint concentrations after ACLR or its effect on supposed allograft contamination. Nevertheless, the present study provides evidential support for the use of vancomycin ACL graft soaking during ACLR in the daily clinical practice.

## Conclusion

The data presented here have led to the conclusion that the harvesting and processing of ACL grafts cause bacterial contamination in 14% of all cases. This contamination is fully eradicated after soaking the grafts in the vancomycin solution.

## Compliance with ethical standards

**Conflict of interest** We have no potential conflict of interest.

## References

1. Alomar AZ, Somily AM, Alraiyes TM, Bin Nasser AS, Aljassir FF (2016) Quantification analysis of the intraoperative bacterial contamination rate and level in osteochondral Autografts. *Am J Sports Med* 44:761–766
2. Badran MA, Moemen DM (2016) Hamstring graft bacterial contamination during anterior cruciate ligament reconstruction: clinical and microbiological study. *Int Orthop* 40:1899–1903
3. Bostrom Windhamre H, Mikkelsen C, Forssblad M, Willberg L (2014) Postoperative septic arthritis after anterior cruciate ligament reconstruction: does it affect the outcome? A retrospective controlled study. *Arthroscopy* 30:1100–1109
4. Brophy RH, Wright RW, Huston LJ, Nwosu SK, Spindler KP (2015) Factors associated with infection following anterior cruciate ligament reconstruction. *J Bone Joint Surg Am* 97:450–454
5. Cadet ER, Makhni EC, Mehran N, Schulz BM (2013) Management of septic arthritis following anterior cruciate ligament reconstruction: a review of current practices and recommendations. *J Am Acad Orthop Surg* 21:647–656
6. Camarda L, Pitarresi G, Moscadini S, Marannano G, Sanfilippo A, D'Arienzo M (2014) Effect of suturing the femoral portion of a four-strand graft during an ACL reconstruction. *Knee Surg Sports Traumatol Arthrosc* 22:1040–1046
7. Edin ML, Miclau T, Lester GE, Lindsey RW, Dahners LE (1996) Effect of cefazolin and vancomycin on osteoblasts in vitro. *Clin Orthop Relat Res* 333:245–251
8. Gavriilidis I, Pakos EE, Wipfler B, Benetos IS, Paessler HH (2009) Intra-operative hamstring tendon graft contamination in anterior cruciate ligament reconstruction. *Knee Surg Sports Traumatol Arthrosc* 17:1043–1047
9. Grayson JE, Grant GD, Dukie S, Vertullo CJ (2011) The in vitro elution characteristics of vancomycin from tendons. *Clin Orthop Relat Res* 469:2948–2952
10. Hantes ME, Basdekis GK, Varitimidis SE, Giotikas D, Petinaki E, Malizos KN (2008) Autograft contamination during preparation for anterior cruciate ligament reconstruction. *J Bone Joint Surg Am* 90:760–764
11. Heng CHY, Wang BDH, Chang PCC (2015) Distal femoral fracture after double-bundle anterior cruciate ligament reconstruction surgery. *Am J Sports Med* 43:953–956
12. Jones KJ, Lazaro LE, Taylor SA, Pardee NC, Dyke JP, Hannafin JA, Warren RF, Lorch DG (2016) Quantitative assessment of patellar vascularity following bone-patellar tendon-bone autograft harvest for ACL reconstruction. *Knee Surg Sports Traumatol Arthrosc* 24:2818–2824

13. Kursumovic K, Charalambous CP (2016) Graft salvage following infected anterior cruciate ligament reconstruction: a systematic review and meta-analysis. *Bone Joint J* 98–B:608–615
14. Lubowitz JH (2015) Editorial commentary: hamstring autografts are more frequently associated with ACL infection. *Arthroscopy* 31:1402
15. Maletis GB, Inacio MCS, Reynolds S, Desmond JL, Maletis MM, Funahashi TT (2013) Incidence of postoperative anterior cruciate ligament reconstruction infections: graft choice makes a difference. *Am J Sports Med* 41:1780–1785
16. Mayr HO, Brandt CM, Weig T, Koehne M, Bernstein A, Suedkamp NP, Hube R, Stoehr A (2016) Long-term results of arthroscopic arthrolysis for arthrofibrosis after anterior cruciate ligament reconstruction. *Arthroscopy* 33:408–414
17. Mei-Dan O, Mann G, Steinbacher G, Ballester SJ, Cugat RB, Alvarez PD (2008) Septic arthritis with *Staphylococcus lugdunensis* following arthroscopic ACL revision with BPTB allograft. *Knee Surg Sports Traumatol Arthrosc* 16:15–18
18. Nakayama H, Yagi M, Yoshiya S, Takesue Y (2012) Micro-organism colonization and intraoperative contamination in patients undergoing arthroscopic anterior cruciate ligament reconstruction. *Arthroscopy* 28:667–671
19. Perez-Prieto D, Torres-Claramunt R, Gelber PE, Shehata TMA, Pelfort X, Monllau JC (2014) Autograft soaking in vancomycin reduces the risk of infection after anterior cruciate ligament reconstruction. *Knee Surg Sports Traumatol Arthrosc* 24:2724–2728
20. Perez-Prieto D, Trampuz A, Torres-Claramunt R, Eugenia Portillo M, Puig-Verdie L, Monllau JC (2016) Infections after anterior cruciate ligament reconstruction: which antibiotic after arthroscopic debridement? *J Knee Surg* 30:309–313
21. Phegan M, Grayson JE, Vertullo CJ (2016) No infections in 1300 anterior cruciate ligament reconstructions with vancomycin pre-soaking of hamstring grafts. *Knee Surg Sports Traumatol Arthrosc* 24:2729–2735
22. Portillo ME, Corvec S, Borens O, Trampuz A (2013) *Propionibacterium acnes*: an underestimated pathogen in implant-associated infections. *Biomed Res Int* 2013:804391
23. Saper M, Stephenson K, Heisey M (2014) Arthroscopic irrigation and debridement in the treatment of septic arthritis after anterior cruciate ligament reconstruction. *Arthroscopy* 30:747–754
24. Schuster P, Schulz M, Immendoerfer M, Mayer P, Schlumberger M, Richter J (2015) Septic arthritis after arthroscopic anterior cruciate ligament reconstruction: evaluation of an arthroscopic graft-retaining treatment protocol. *Am J Sports Med* 43:3005–3012
25. Shah NB, Osmon DR, Fadel H, Patel R, Kohner PC, Steckelberg JM, Mabry T, Berbari EF (2010) Laboratory and clinical characteristics of *Staphylococcus lugdunensis* prosthetic joint infections. *J Clin Microbiol* 48:1600–1603
26. Sonnery-Cottet B, Thaunat M, Archbold P, Issartel B, Cadet ER (2014) Management of septic arthritis following anterior cruciate ligament reconstruction: a review of current practices and recommendations. *J Am Acad Orthop Surg* 22:271–273
27. Torres-Claramunt R, Gelber P, Pelfort X, Hinarejos P, Leal-Blanquet J, Perez-Prieto D, Monllau JC (2016) Managing septic arthritis after knee ligament reconstruction. *Int Orthop* 40:607–614
28. Torres-Claramunt R, Pelfort X, Erquicia J, Gil-Gonzalez S, Gelber PE, Puig L, Monllau JC (2013) Knee joint infection after ACL reconstruction: prevalence, management and functional outcomes. *Knee Surg Sports Traumatol Arthrosc* 21:2844–2849
29. Vertullo CJ, Quick M, Jones A, Grayson JE (2012) A surgical technique using presoaked vancomycin hamstring grafts to decrease the risk of infection after anterior cruciate ligament reconstruction. *Arthroscopy* 28(3):337–342
30. Zimmerli W (2014) Clinical presentation and treatment of orthopaedic implant-associated infection. *J Intern Med* 276:111–119
31. Zimmerli W, Trampuz A, Ochsner PE (2004) Prosthetic-joint infections. *N Engl J Med* 351:1645–1654